



De Belgische gezondheidsautoriteiten hebben bepaalde voorwaarden verbonden aan het in de handel brengen van het geneesmiddel Radelumin®. Het verplicht plan voor risicobeperking in België, waarvan deze informatie deel uitmaakt, is een maatregel genomen om een veilig en doeltreffend gebruik van Radelumin® te waarborgen (RMA versie 04/2024).

Les autorités belges de santé publique ont assorti la mise sur le marché du médicament Radelumin® de certaines conditions. Le plan obligatoire de minimisation des risques en Belgique et au Luxembourg, dont cette information fait partie, est une mesure prise pour garantir une utilisation sûre et efficace du médicament Radelumin® (RMA version 04/2024)

Radelumin® ([¹⁸F]PSMA-1007) support pédagogique pour les professionnels de la santé

- ▼ Dit geneesmiddel is onderworpen aan aanvullende monitoring.
Ce médicament fait l'objet d'une surveillance supplémentaire.

Dit materiaal bevat niet alle informatie. Voor de volledige informatie: Lees aandachtig de SKP vooraleer Radelumin® voor te schrijven en/of te gebruiken en/of af te leveren. De volledige en geactualiseerde tekst van deze SKP is beschikbaar op de website www.fagg.be, rubriek "Zoek informatie over een vergund geneesmiddel"

Ce matériel ne contient pas toutes les informations. Pour une information complète, lisez attentivement le RCP avant de prescrire et/ou d'utiliser et/ou de délivrer Radelumin®. Le texte complet et actualisé de ce RCP est disponible sur le site www.afmps.be, rubrique « Chercher des informations sur un médicament autorisé »

Contents

- Document Objective: Training on Interpreting [¹⁸F]PSMA-1007 Images
- Legal Disclosures
- Introduction to [¹⁸F]PSMA-1007 (Radelumin®): Clinical Indications
- Biochemical Basics
 - Chemical Structure of [¹⁸F]PSMA-1007
 - PSMA
 - Mechanism of Uptake
- Patient Administration and Scanning Protocol
 - Patient Preparation
 - Injection Recommendations
 - Scanning Protocol
- Image Reading and Interpretation Guidelines
 - Special Warnings and Precaution for Use
 - Guidelines and Practical Tips
 - PSMA Visual Assessment Scoring Scale
 - [¹⁸F]PSMA-1007 PET in the Context of Other Imaging Modalities

Contents

■ Physiological Distribution

- Physiological distribution of [^{18}F]PSMA-1007 - patient after radiation therapy

■ Primary Staging of Patients with High-Risk Prostate Cancer

- Unifocal Tumor
- Multifocal Tumor
- Multifocal Tumor with Pelvic Lymph Node Metastases
- Multifocal Tumor with Distant Metastases

■ Restaging in Patients with Suspected Recurrence

- Local Recurrence
- Local Lymph Node Metastasis (Iliac)
- Distant Lymph Node Metastases (Retroperitoneal)
- Distant Lymph Node Metastases (Mediastinal)
- Distant Lymph Node Metastases (Supraclavicular - Virchow's Lymph Node)
- Lung Metastases (Case 1)
- Lung Metastases (Case 2)
- Single Bone Metastasis
- Oligometastatic Bone Metastases
- Disseminated Bone Metastases
- Diffuse Bone Marrow Infiltration
- Liver Metastases

Contents

■ Rare Locations of Metastases

- Penis Metastasis
- Retinal, Adrenal & Meningeal Metastases
- Retroareolar, cutaneous, subcutaneous and muscle metastases

■ Unspecific Bone Uptake

■ Specific Bone Uptake

- Osteoid Osteoma
- Therapy Related False Positives
- Rib fracture
- Paget Disease

■ Other Malignancies with PSMA-Expression (examples)

- Hepatocellular carcinoma (HCC)
- Adenoid Cystic Carcinoma (ACC)

Contents

■ Pitfalls

- Ganglia of the Sympathetic Trunk
- Sarcoidosis
- Accessory Salivary Glands
- Residual activity in the Bladder and Left Ureter

■ Self-Evaluation Examination

■ List of Supplementary Videos

■ Abbreviation List

■ Bibliography

■ Adverse Event Reporting

Document Objective: Training on Interpreting [^{18}F]PSMA-1007 Images

- [^{18}F]PSMA-1007 image interpretation training has been created as an additional tool to assist you in becoming familiar with techniques for a safe and effective use.
- This training offers crucial information regarding the risks linked to misinterpretation of PSMA PET imaging.
- In order to highlight certain findings at a quick glance, the windowing of the images has been adjusted (where applicable) in a region that differs from the clinical workflow.
- The whole-body images of the patients are 2D screenshots from MIPs. The line of sight has been clarified and is denoted using the following abbreviations:
 - A: from anterior (front)
 - L: from left
 - R: from right
 - P: from posterior (back)
- The interpretation of all cases presented was consistent among three readers. A nuclear medicine specialist initially evaluated the cases, and the interpretation was validated by two other specialists (a nuclear medicine physician and a radiologist).

Legal Disclosures

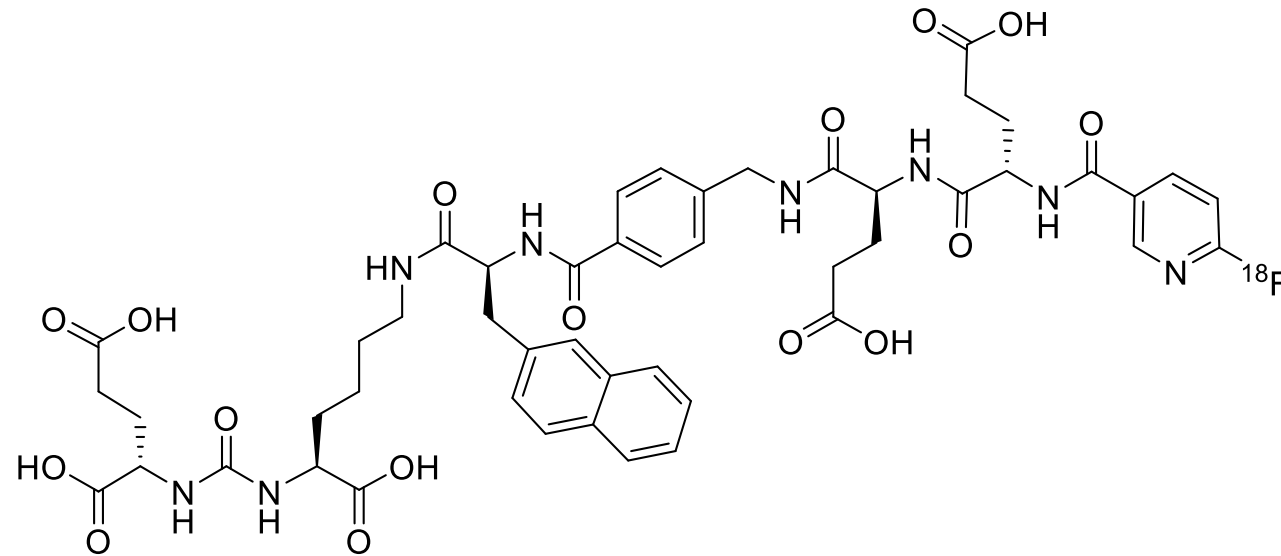
- Expert recommendations in accordance with the EAU-EANM-ASTRO-ESUR-ISUP-SIOG guidelines on Prostate cancer
- Local law, national regulations, and guidelines are not affected by the information presented; these should be taken into consideration
- The [^{18}F]PSMA-1007 image interpretation training has been created as an additional tool to assist you in becoming familiar with techniques for using [^{18}F]PSMA-1007 safely and effectively.
- The accurate and timely acquisition and interpretation of images using PSMA PET/CT scanning is the responsibility of the nuclear medicine physician or radiologist overseeing the PET/CT imaging facility.
- The PSMA image interpretation training is intended to supplement the physician's knowledge of techniques for safe and effective usage of PSMA and is not a replacement for their independent medical judgment in managing individual patients. Furthermore, completion of the PSMA image interpretation training does not guarantee any specific clinical outcomes.
- The [^{18}F]PSMA-1007 Reader Training HCPs was prepared with support of Dr. Himmen and Dr. Telli and reviewed by Dr. Herrmann from the University Hospital Essen.

Introduction to [^{18}F]PSMA-1007 (Radelumin[®]): Clinical Indications

- This medicinal product is for diagnostic use only.
- Radelumin is indicated for the detection of prostate-specific membrane antigen (PSMA)-positive lesions with positron emission tomography (PET) in adults with prostate cancer (PCa) in the following clinical contexts:
 - Primary staging of patients with high-risk PCa prior to primary curative therapy,
 - Suspected PCa recurrence in patients with increasing levels of serum prostate-specific antigen (PSA) after primary curative therapy.

Biochemical Basics

Chemical Structure of [^{18}F]PSMA-1007



Biochemical Basics - PSMA

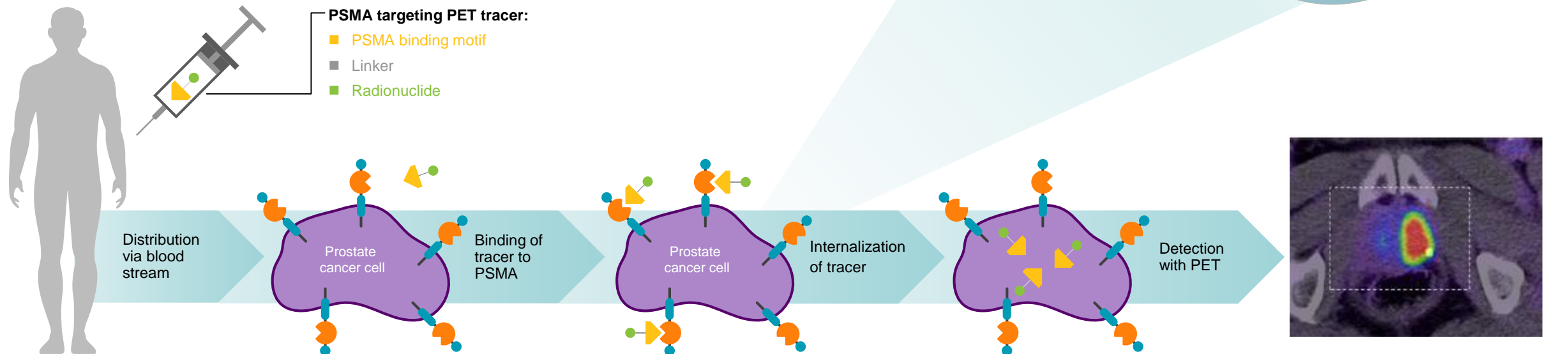
- PSMA: prostate specific membrane antigen also known as glutamate carboxypeptidase II (GCPII)
 - Hydrolysis of N-acetylaspartylglutamate (NAAG) to glutamate and N-acetylaspartate (NAA)
- Cell surface protein, mainly expressed in:
 - Prostate epithelium
 - Proximal tubules of the kidney(s)
 - Brush border of the small intestine
 - Ganglia of the nervous system
 - Salivary and lacrimal glands
 - Liver and spleen

Physiological
(level of expression may vary)
- PSMA expression in Prostate cancer tissue is up to 100- to 1000-fold higher than in physiological prostate tissue
 - The function of PSMA is still widely unknown, although there is some suggestion that it may be involved in the neuroendocrine regulation of prostate growth and differentiation.
 - Expression correlates with cancer aggressiveness

Demirci E, et al. Nucl Med Commun. 2016;37(11):1169–1179; Ristau BT, et al. Urol Oncol. 2014;32(3):272–279.

Biochemical Basics - Mechanism of Uptake

- IV injection
- Transport to tumor site / organs via the blood stream
- Binding to PSMA protein on the cell surface
- Internalization via endocytosis (trapping inside cell)
- Radiation of bound and internalized [^{18}F]PSMA-1007 allow for PET imaging



Patient Administration and Scanning Protocol - Patient Preparation

- The following documents should be provided for proper scan interpretation:
 - Previous reports, including recent lab results
 - PSA-kinetics, Gleason-Score
 - Kidney and thyroid results (if iodinated contrast-enhanced CT is planned)
 - Recent history of prostate cancer-specific medications and treatments
- Additional information that should be provided to patients:
 - Information about duration of the procedure (2-4 hours, depending on the site-specific protocol)
 - Fasting is not required; most medications can be taken prior to the scan
- Prior appointment confirmation is recommended in order to reduce down-time

Patient Administration and Scanning Protocol - Patient Preparation

■ Patient preparation:

- Prior to administration of [^{18}F]PSMA-1007, patients should be adequately hydrated and advised to empty their bladder immediately before and frequently during the initial hours following image acquisition to minimize radiation exposure

■ Injection:

■ Recommended dosage:

- 3.6-4.4 MBq per kg body weight
- For a 70 kg patient, 252-308 MBq (6.8-8.3 mCi)

- Handle [^{18}F]PSMA-1007 injection with appropriate safety measures in accordance with local laws and regulations to minimize radiation exposure

Patient Administration and Scanning Protocol - Injection Recommendation

- The maximum activity injected should not exceed 450 MBq. The maximum volume of solution for injection should not exceed 10mL
- The activity of [^{18}F]PSMA-1007 has to be measured with an activimeter immediately prior to injection
- No dose adjustment is considered necessary in patients with renal/hepatic impairment
- Withdrawals should be performed under aseptic conditions. Adequate shielding is mandatory
- The vial must not be opened before disinfecting the stopper, the solution should be withdrawn via the stopper using a single dose syringe fitted with suitable protective shielding and disposable sterile needle or using an authorized automated application system
- If the integrity of this vial is compromised, the product should not be used
- The solution should be inspected visually prior to use. Only clean solutions, free from visible particles should be used
- [^{18}F]PSMA-1007 may be diluted with sterile sodium chloride 9 mg/mL (0.9%) solution immediately before use

Patient Administration and Scanning Protocol - Scanning Protocol

- It is recommended to acquire [^{18}F]PSMA-1007 PET images by scanning the entire body starting from the mid-thigh and proceeding to the skull vertex. PET images should be taken 90 to 120 minutes following the intravenous injection of [^{18}F]PSMA-1007 solution.
- Multiple variants and combinations of scanning protocols are possible and should always be adapted to the equipment used, the patient, and the tumor characteristics in order to obtain the best image quality possible.

Patient Administration and Scanning Protocol - Scanning Protocol

- The authors provide the following practical recommendations:

- CT scan

- Low dose without contrast agent
- Full dose without contrast agent
- Full dose contrast-enhanced (in accordance with ESUR Guideline)
- Arms should be positioned above head to avoid artifacts
- Depending on clinical requirements, from skull base to mid-thigh (scan direction as per local protocol)

- PET scan

- Depending on clinical requirements, from mid-thigh to skull vertex (coverage identical to CT scan) - scan direction from pelvis to head (scan direction as per local protocol)
- 2-4 min per bed position or equivalent continuous motion
- Reconstruction with and without attenuation correction
- Confirm quality immediately after scan

Image Reading and Interpretation Guidelines - Special Warnings and Precaution for Use

- [^{18}F]PSMA-1007 images should be visually interpreted by appropriately nuclear medicine specialists trained in [^{18}F]PSMA-1007 PET
- Suspicion of cancerous tissue in sites typical for prostate cancer recurrence is based on [^{18}F]PSMA-1007 uptake at these sites relative to that of the background and side-by-side evaluation of information from corresponding CT and/or MRI
- Known physiological uptake of PSMA-targeting tracers should be taken into consideration:
 - Kidneys
 - lacrimal and salivary glands
 - liver
 - gallbladder
 - Spleen and pancreas

Image Reading and Interpretation Guidelines - Special Warnings and Precaution for Use

- PET imaging interpretation errors include, but are not limited to:
 - Other types of cancer
 - Benign bone diseases
 - Inflammatory processes in activated lymph nodes
 - Benign thyroid diseases
 - Liver inflammation
 - Prostatitis
 - Benign prostatic hyperplasia
 - Gliomas
 - Healing rib fractures
 - Ganglia can mimic lymph nodes
 - Focal unspecific bone uptake

Image Reading and Interpretation Guidelines - Special Warnings and Precaution for Use

- Diagnostic performance of [18F]PSMA-1007 may be affected by:
 - Serum PSA levels
 - Androgen-receptor targeting treatments
 - prostate cancer disease stage
 - Size of malignant lymph nodes (lesions smaller than 4mm may be missed due to limited spatial resolution of PET/CT)
- Further investigation, which may include histopathological evaluation of the suspected lesions, should be considered where appropriate.

Image Reading and Interpretation Guidelines - Guidelines and Practical Tips

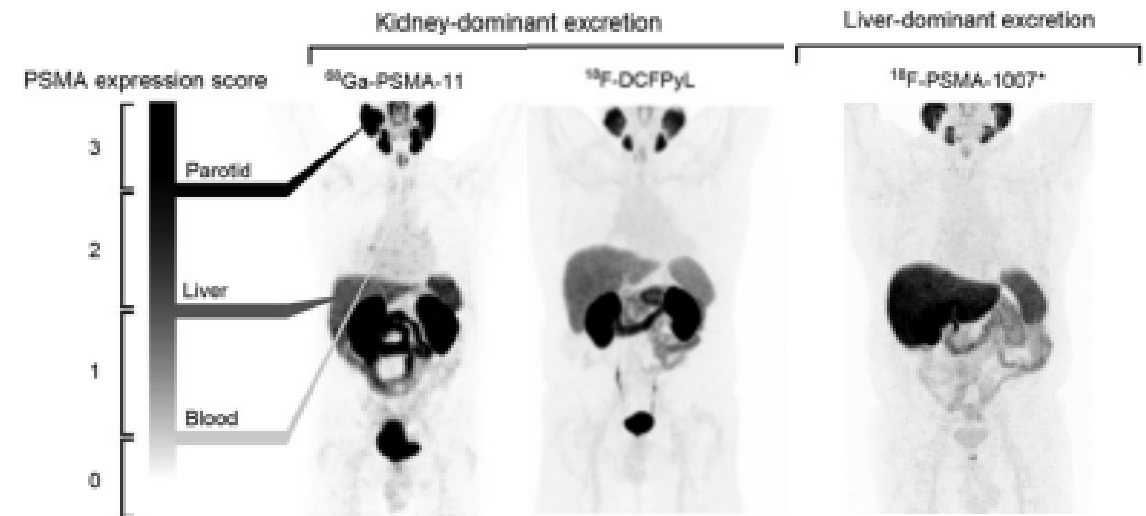
- For comprehensive instructions on image interpretation and reading of PET and PSMA PET, it is recommended to consult official guidelines such as the joint EANM and SNMMI procedure guidelines.
- The authors provide the following practical recommendations:
 - Prior to image analysis, ensure that the patient's complete name, date of birth, and the examination date are correct
 - Verify that the appropriate weight, height, activity, and acquisition time have been entered to prevent inaccurate visual uptake and SUV measurements
 - Take into consideration the patient's medical history
 - Utilize all available series and images, including CT/MRI, PET, fusion, and prior examinations if available.
 - Known physiological uptake of PSMA-targeting tracers should be taken into consideration:
 - Kidneys, lacrimal glands, liver, salivary glands, gallbladder, spleen and pancreas

Image Reading and Interpretation Guidelines - PSMA Visual Assessment Scoring Scale

■ Findings: PSMA uptake score

miPSMA Expression Score

Score	Reported PSMA expression	Uptake
0	No	Below blood pool
1	Low	Equal to or above blood pool and lower than liver*
2	Intermediate	Equal to or above liver* and lower than parotid gland
3	High	Equal to or above parotid gland



Eiber M et al. [published correction appears in J Nucl Med. 2018 Jun;59(6):992]. J Nucl Med. 2018;59(3):469-478.

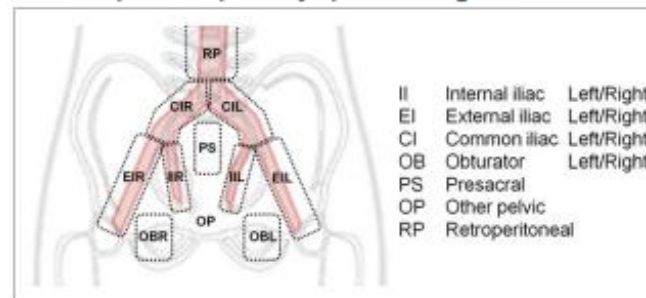
Image Reading and Interpretation Guidelines - PSMA Visual Assessment Scoring Scale

- Findings: sextant segmentation of prostate, lymph nodes, pattern of bone involvement

Sextant Segmentation of Prostate Gland

Segment	miT2-4 template
LB	Left base
RB	Right base
LM	Left mid
RM	Right mid
LA	Left apex
RA	Right apex

template for pelvic lymph node regions.

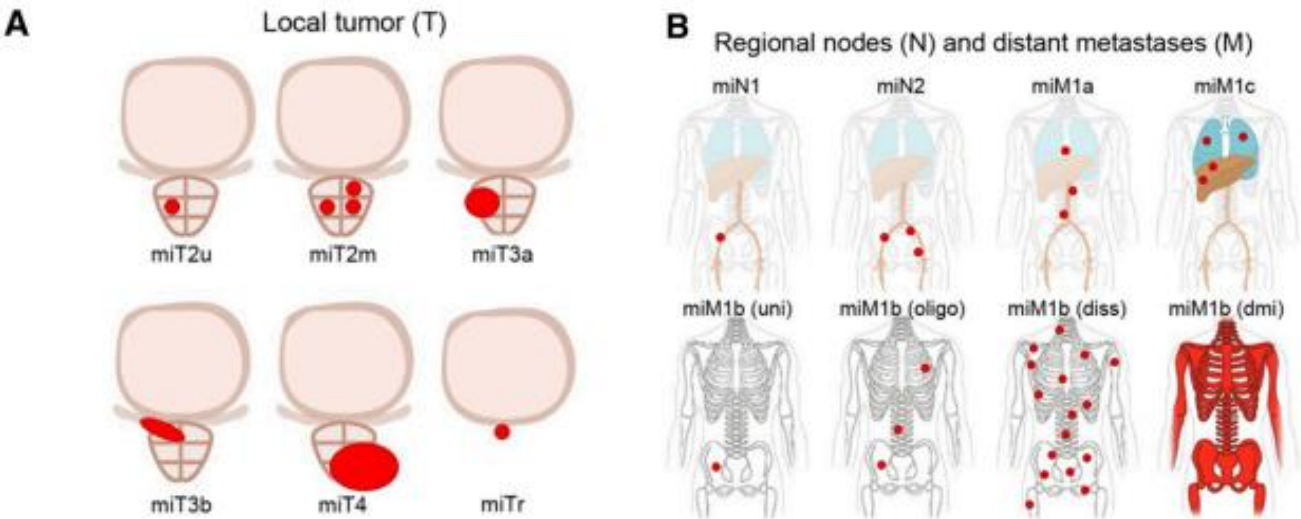


Pattern of Bone Involvement

Abbreviation	Pattern of bone involvement
Uni	Unifocal
Oligo	Oligometastatic ($n \leq 3$)
Diss	Disseminated
Dmi	Diffuse marrow involvement

Image Reading and Interpretation Guidelines - PSMA Visual Assessment Scoring Scale

■ Comment: Certainty of final diagnosis, miTNM score



Certainty and Final Diagnosis	
Certainty	Diagnosis
Consistent with	Positive
Suggestive of	Positive
Possible	Equivocal
Unlikely	Negative
No evidence of disease	Negative

Eiber M et al. [published correction appears in J Nucl Med. 2018 Jun;59(6):992]. J Nucl Med. 2018;59(3):469-478.

Image Reading and Interpretation Guidelines - PSMA Visual Assessment Scoring Scale

Organ	CT/MRI appearance	PSMA score	Diagnosis
Prostate bed s/p prostatectomy	Soft tissue lesion in prostate bed	≥ 1	Positive
		0	Negative*
	No soft tissue lesion	≥ 2	Positive
		≤ 1	Negative
Prostate s/p radiation therapy	Intraprostatic lesion	≥ 2	Positive
		1	Equivocal
		0	Negative*
	No intraprostatic lesion	≥ 2	Positive
		≤ 1	Negative

Organ	PI/RADS class	PSMA score	Diagnosis
Prostate	V	Any	Positive*
	IV	≥ 1	Positive
		0	Equivocal*
	III	≥ 2	Positive
		1	Equivocal
		0	Negative
	I / II	≥ 2	Positive
		≤ 1	Negative
	No MRI available / PI-RADS not applicable	≥ 2	Positive
		≤ 1	Negative

Eiber M et al. [published correction appears in J Nucl Med. 2018 Jun;59(6):992]. J Nucl Med. 2018;59(3):469-478.

Image Reading and Interpretation Guidelines - PSMA Visual Assessment Scoring Scale

Organ	CT/MRI appearance	PSMA score	Diagnosis
Lymph node	SD ≥8 mm OR contrast enhancement	≥1	Positive
		0	Negative*
	Unremarkable	Pelvic/retroperitoneal LN regions	
		≥1	Positive
		0	Negative
		Other LN regions	
		≥2	Positive
		≤1	Negative
	Common pitfall incl. suspected inflammation OR Suspected non-PCa malignancy	3	Consider positive
		2	Equivocal
		≤1	Negative

Organ	CT/MRI appearance	PSMA score	Diagnosis
Bone / visceral organ	Suspicious lesion	≥1	Positive
		0	Negative*
	Equivocal lesion	≥2	Positive
		≤1	Negative
	No lesion	Single focus	
		3	Positive
		2	Equivocal
		≤1	Negative
		Multiple foci	
		≥2	Positive
		≤1	Negative
	Benign lesion OR non-PCa malignant tumor	3	Consider positive
		≤2	Negative

Eiber M et al. [published correction appears in J Nucl Med. 2018 Jun;59(6):992]. J Nucl Med. 2018;59(3):469-478.

[¹⁸F]PSMA-1007 PET in the Context of Other Imaging Modalities

- [¹⁸F]PSMA-1007 PET in the context of other imaging modalities:
 - [¹⁸F]PSMA-1007 outperformed conventional imaging modalities (99mTc-hydroxymethylene diphosphonate bone scan; contrast enhanced CT of thorax, abdomen, and pelvis) for the detection of distant metastases (M-staging).
 - Sensitivity at patient level above 90% whereas sensitivity of the other imaging modalities was below 67%
 - The use of PET/CT fusion leads to better anatomical correlation of findings, resulting in increased accuracy of assessment and reduction in image interpretation errors


[¹⁸F]PSMA-1007 PET in the Context of Other Imaging Modalities

- [¹⁸F]PSMA-1007 PET in the context of histopathology:
 - [¹⁸F]PSMA-1007 PET cannot replace histopathology
 - [¹⁸F]PSMA-1007 can help in the selection of suitable tumor locations for biopsy to ensure the best possible staging
 - Evidence of efficacy of [¹⁸F]PSMA-1007 for the detection of N1 nodal disease in comparison to histopathology:

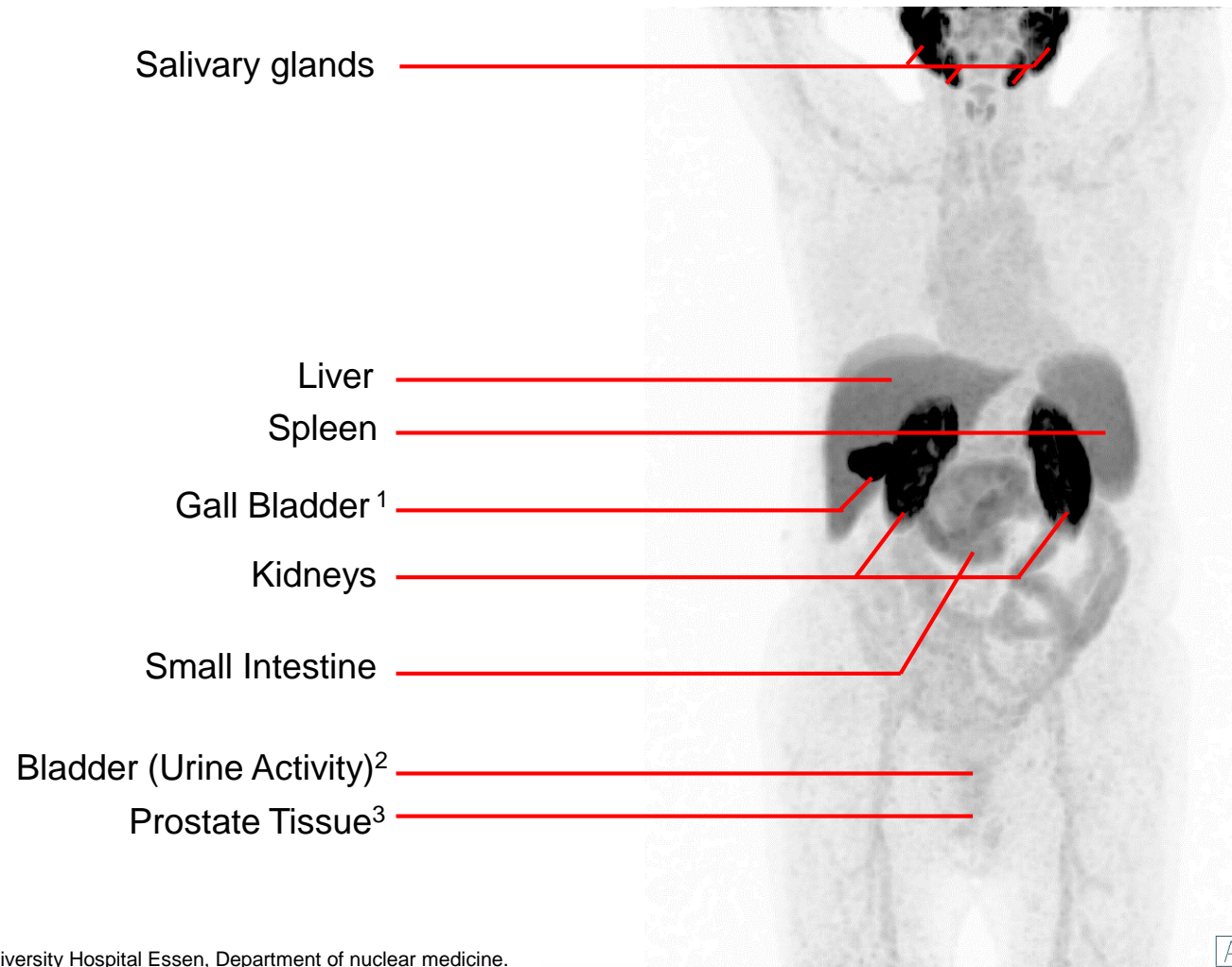
	Patient-based n=99 (Hermsen et al.)	Patient-based n=96 (Sprute et al.)	Patient-based (lymph nodes >3 mm) n=96 (Sprute et al.)	Lesion-based N=1746 dissected lymph nodes (Sprute et al.)	Lesion-based (lymph nodes >3 mm) N=1746 dissected lymph nodes (Sprute et al.)
Sensitivity (95% CI)	53,3 % (34,4-71,7 %)	50,0 %	64,3 %	71,2 %	81,7 %
Specificity (95% CI)	89,9 % (80,2-95,8 %)	89,7 %	91,2 %	99,5 %	99,6 %
PPV (95% CI)	69,6 % (51,2-83,3 %)	66,7 %	75,0 %	91,3 %	92,4 %
NPV (95% CI)	81,6 % (75,0-86,8 %)	81,3 %	86,1 %	97,9 %	98,9 %

Sprute et al, JNM. 2021 Feb;62(2):208-213; Hermsen et al, EJNMMI. 2022 Sep;49(11):3929-3937

Physiological Distribution



Physiological distribution of [^{18}F]PSMA-1007 - patient after radiation therapy




^{1,2} [^{18}F]PSMA-1007 is primarily excreted via the hepatobiliary system. The kidneys usually demonstrate intense PSMA expression, but only approximately 2.4% of the injected activity is excreted in the urine through the kidneys 6h after injection. Particularly in cases of prematurely acquired images and non-emptied bladder before image acquisition, there may be a faint urine activity.

³ Prostate tissue physiologically exhibits homogeneous PSMA expression. After radiation therapy, this expression can be significantly reduced. Following a prostatectomy, no **physiological** PSMA expression should be found in the prostate tissue.

Introduction to Image Reading and Physiological Distribution of [^{18}F]PSMA-1007

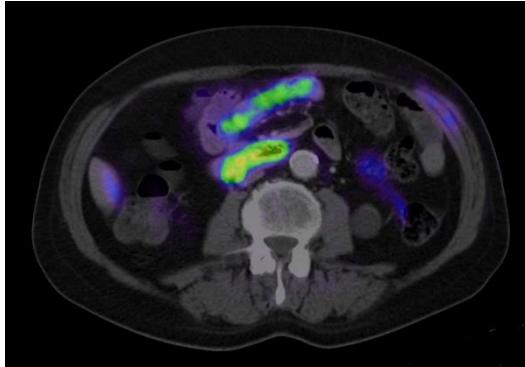


- Please click on the video icon on the right side to open the video or scan the QR code on the left side with your QR app on your smart phone!

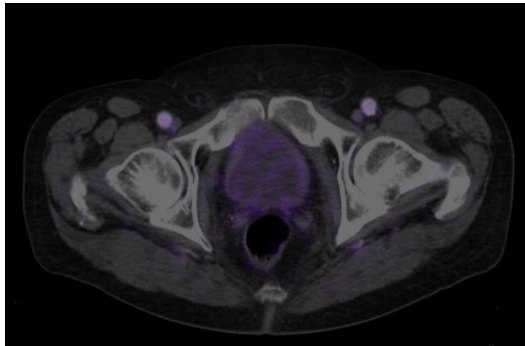


Physiological distribution of [^{18}F]PSMA-1007 - patient after radiation therapy

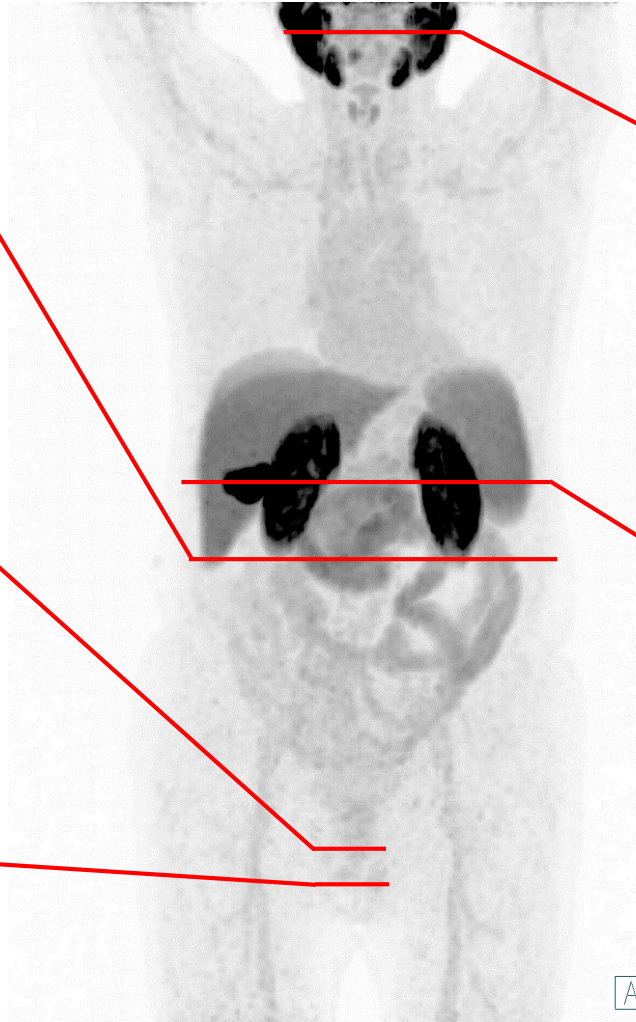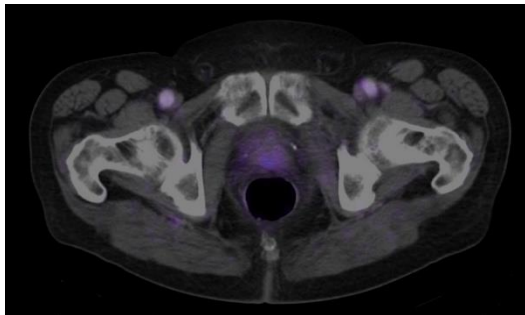
Small Intestine



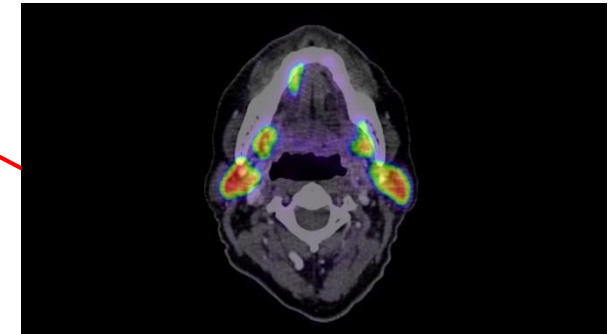
Bladder (Urine Activity)



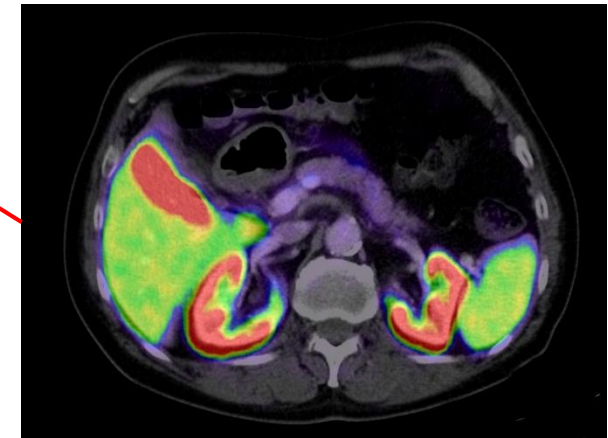
Prostate Tissue



Salivary glands




Liver
Spleen
Gall Bladder
Kidneys

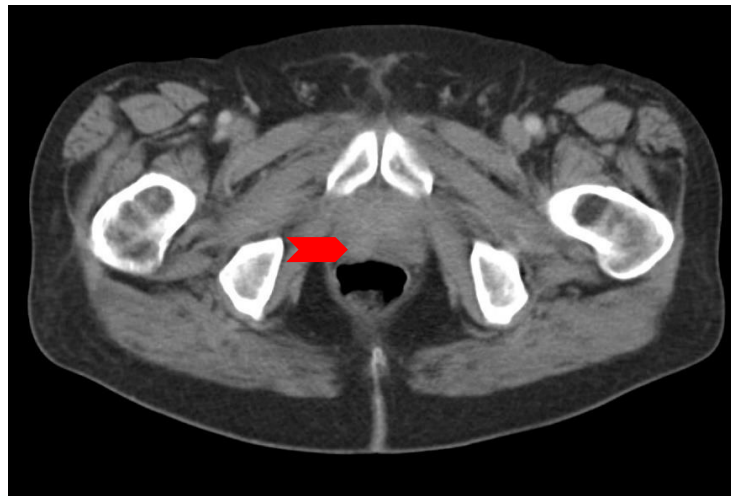
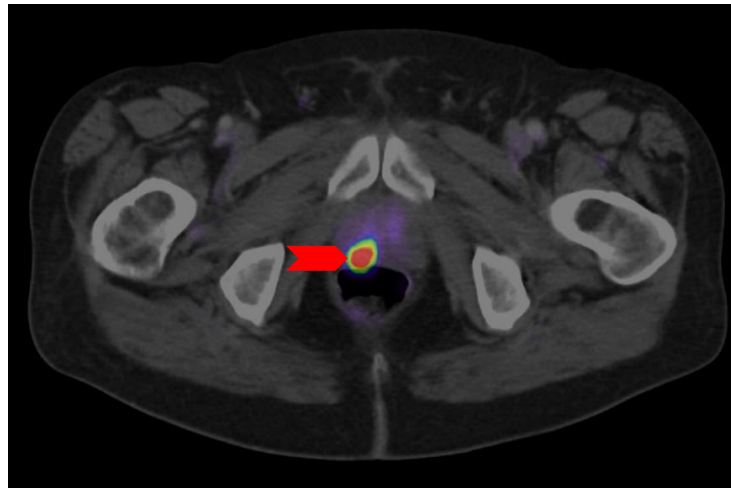
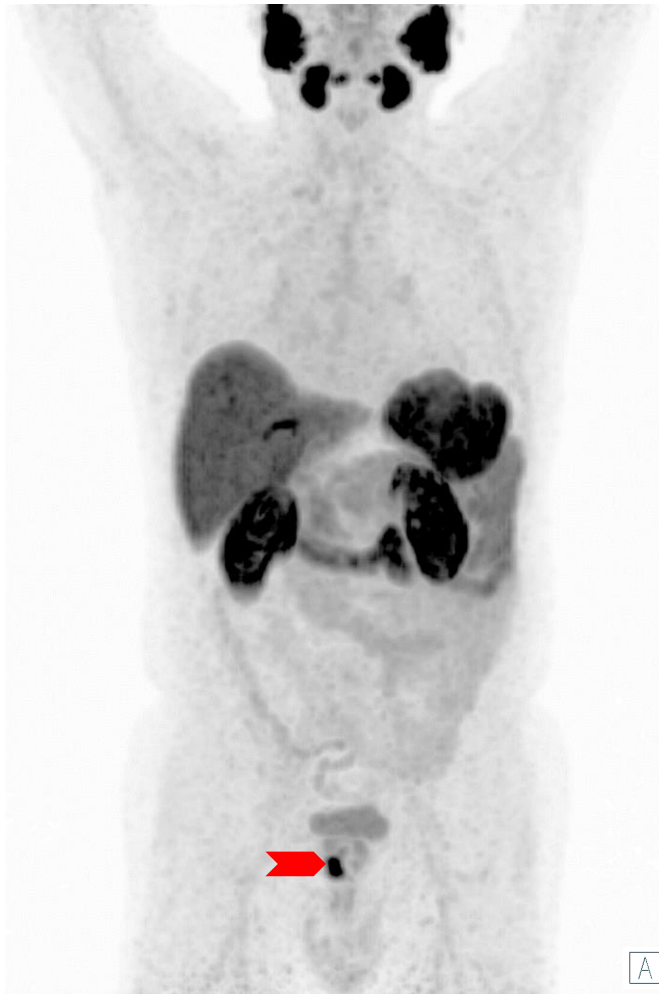

Images: University Hospital Essen, Department of nuclear medicine.

Primary Staging of Patients with High-Risk Prostate Cancer



Primary Staging of Patients with High-Risk Prostate Cancer - Unifocal Tumor




- Healthy prostate tissue exhibits homogeneous PSMA expression above mediastinum and blood pool level
- Prostate carcinomas usually exhibit significantly higher PSMA expression
- Prostate carcinomas with high PSMA expression commonly show a correlate on contrast-enhanced CT (red arrow)
- No other malignancies (with elevated PSMA expression) or prostate cancer metastases are present
- Side note: Patient after cholecystectomy and insufficient voiding of bladder prior to scan (residual urine activity)

Images: University Hospital Essen, Department of nuclear medicine.

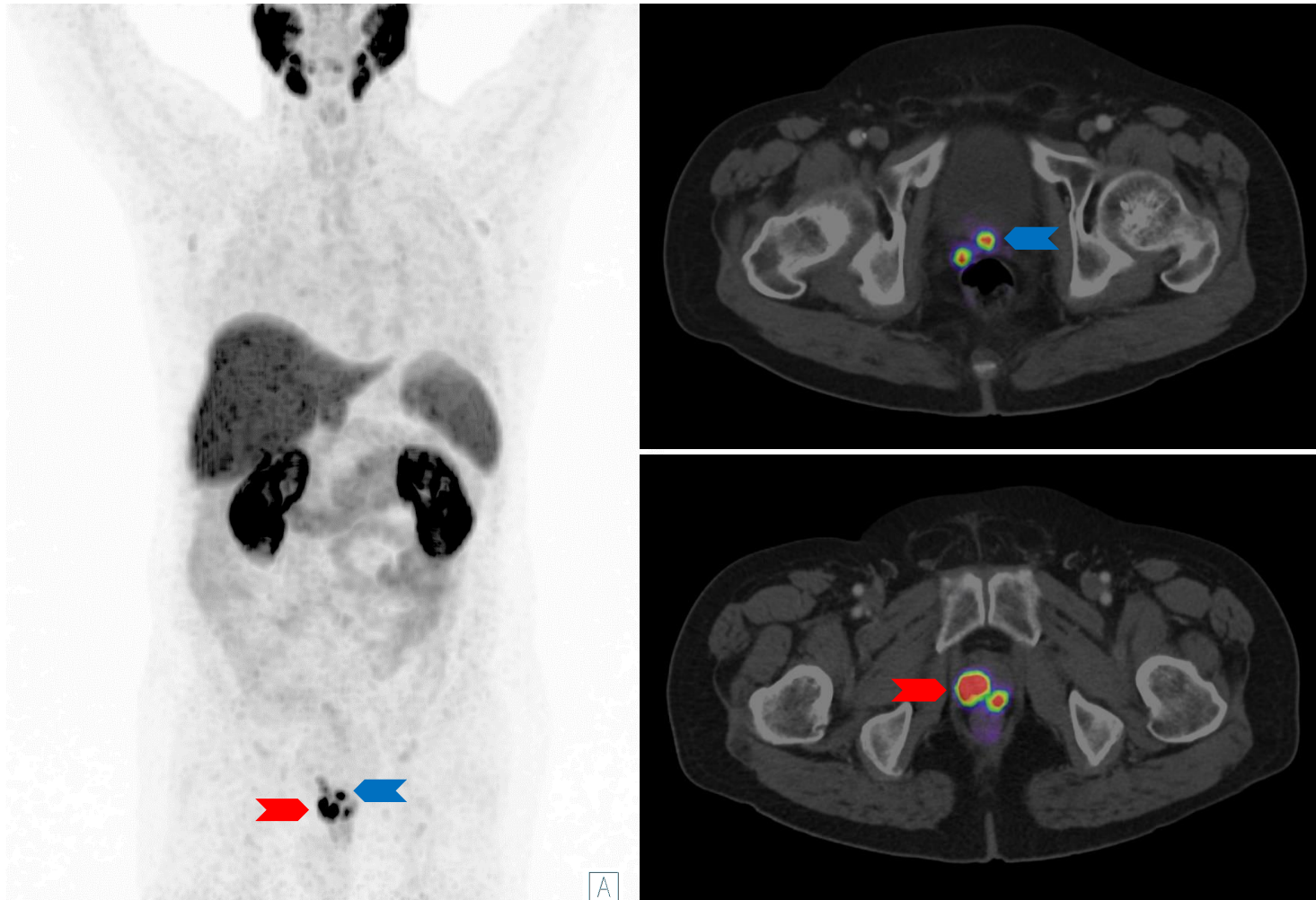
Primary Staging - Unifocal Tumor



- Please click on the video icon on the right side to open the video or scan the QR code on the left side with your QR app on your smart phone!



Primary Staging of Patients with High-Risk Prostate Cancer - Multifocal Tumor



- Multifocal bilateral prostate cancer involvement (red arrows) as well as involvement of posterior wall of bladder and right seminal vesicle (blue arrows)
- The intensity of PSMA expression in individual prostate carcinoma lesions may vary
- Differentiation from areas with local prostatitis, for example after biopsy, can be difficult, as uptake may be increased in these areas
- Side note: Patient after cholecystectomy
- In a study of Privé et al., [^{18}F]PSMA-1007 PET/CT correctly staged 18/53 patients with primary prostate cancer, especially seminal vesicle invasion more often than mp-MRI (90 vs. 76%) [1]


[1] Privé BM, et al. 2021 Jun;24(2):423-430

Images: University Hospital Essen, Department of nuclear medicine.

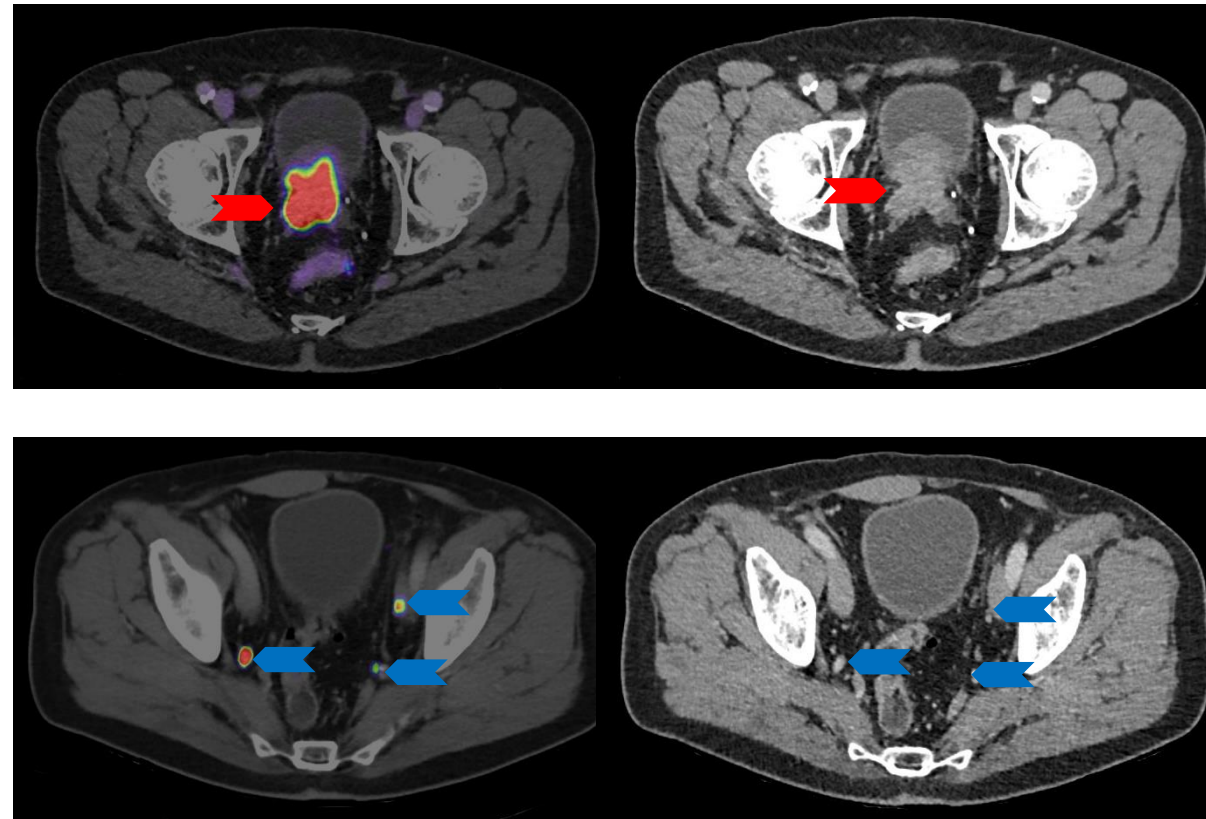
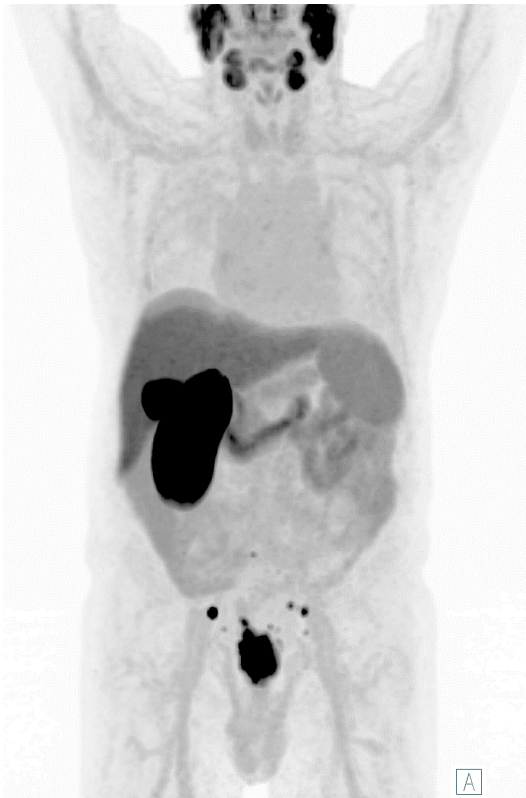Primary Staging - Multifocal Tumor



- Please click on the video icon on the right side to open the video or scan the QR code on the left side with your QR app on your smart phone!



Primary Staging of Patients with High-Risk Prostate Cancer - Multifocal Tumor with Pelvic Lymph Node Metastases




- Gleason Score: 3+5 (Biopsy), initial PSA: 147 ng/ml, initial staging
- Bilateral primary Tumor in the prostate with bilateral seminal vesicle invasion (red arrows)
- Lymph node metastases to the right obturator, left external and internal iliac, and presacral lymph nodes, all with a diameter smaller than 10 mm (blue arrows)

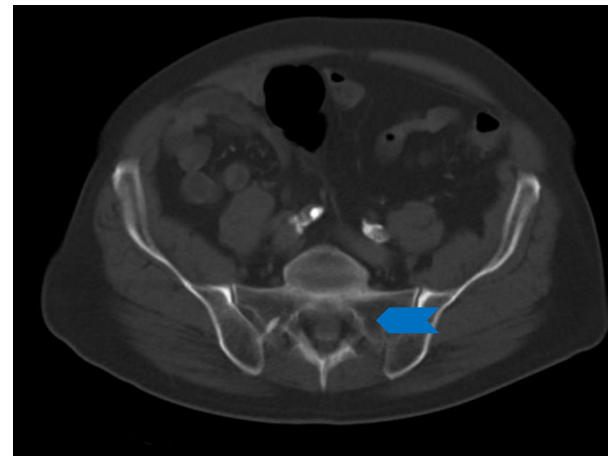
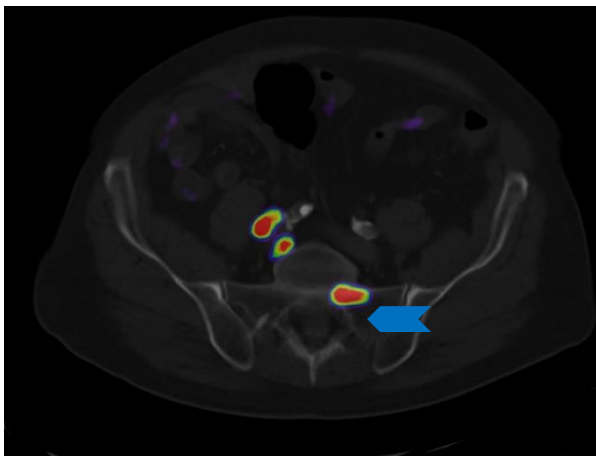
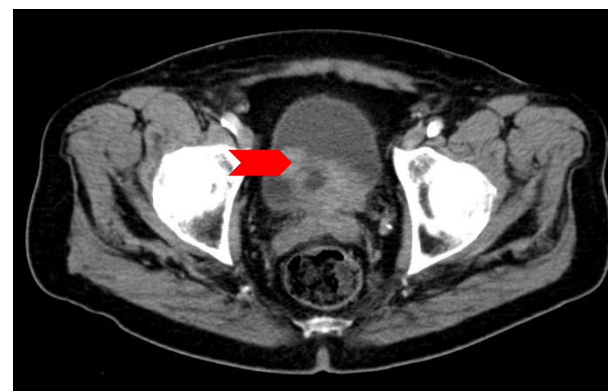
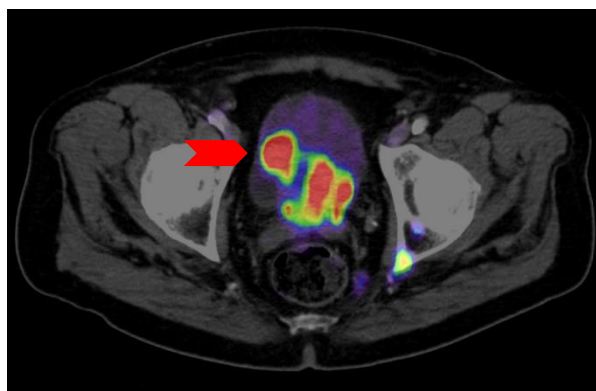
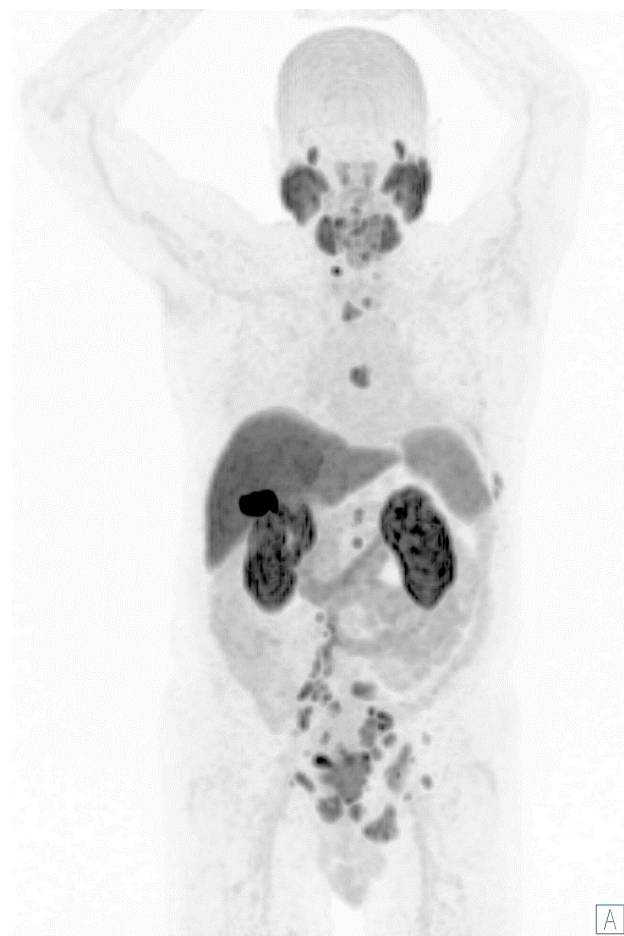Primary Staging - Multifocal Tumor with Pelvic Lymph Node Metastases



- Please click on the video icon on the right side to open the video or scan the QR code on the left side with your QR app on your smart phone!



Primary Staging of Patients with High-Risk Prostate Cancer Multifocal Tumor with Distant Metastases




- Gleason Score 4+4 (Biopsy); Initial PSA: 20 ng/ml
- High-Risk prostate cancer with local bladder and bilateral seminal vesicle invasion (red arrow) as well lymph node and bone metastases (blue arrow)

Images: University Hospital Essen, Department of nuclear medicine.


Primary Staging - Multifocal Tumor with Distant Metastases



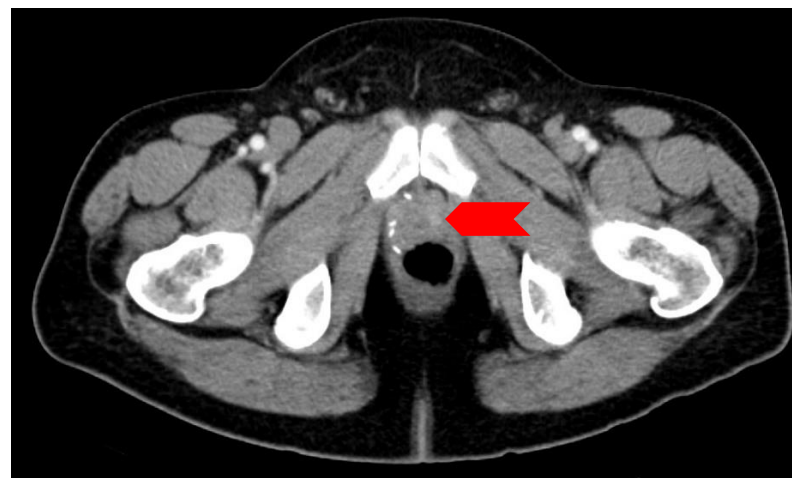
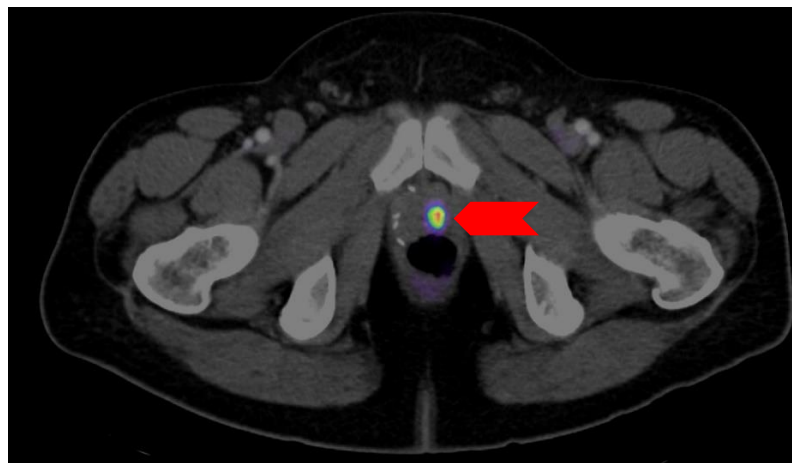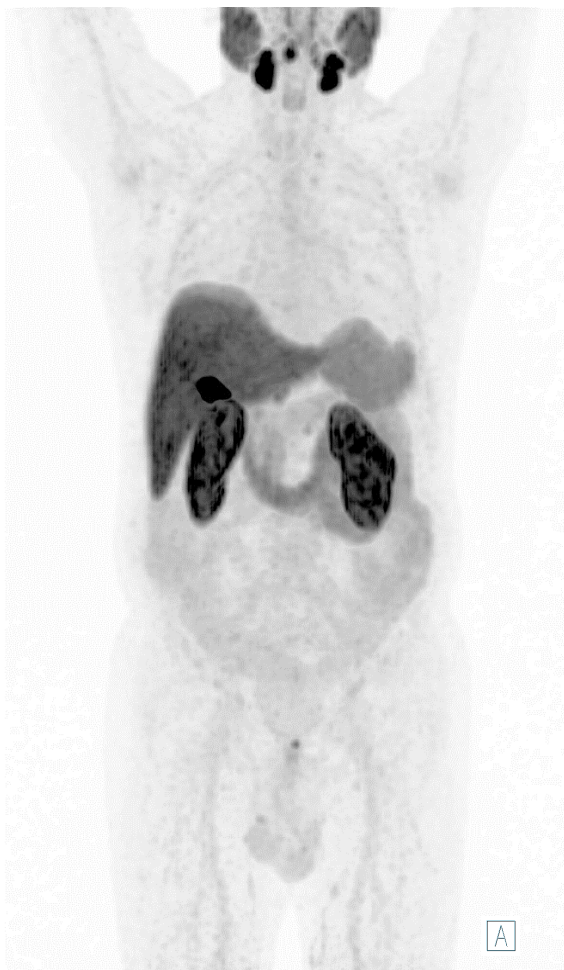- Please click on the video icon on the right side to open the video or scan the QR code on the left side with your QR app on your smart phone!



Restaging in Patients with Suspected Recurrence



Restaging in Patients with Suspected Recurrence - Local Recurrence



- Detection of the disease at lower PSA enables local therapy options and earlier management
- This patient presents a local recurrence with contrast enhancement and focal [^{18}F]PSMA-1007 uptake in the prostatic lobe
- Disease detection rates for [^{18}F]PSMA-1007 were 94.0% (79/84), 90.9% (50/55), 74.5% (35/47), and 61.5% (40/65) for PSA levels of greater than or equal to 2, 1 to less than 2, 0.5 to less than 1, and 0.2 to less than 0.5 ng/mL, respectively. [^{18}F]PSMA-1007 PET/CT revealed local recurrence in 24.7% of patients [1]


Images: University Hospital Essen, Department of nuclear medicine.

[1] Giesel et al. JNM, March 2019, 60(3):362-368

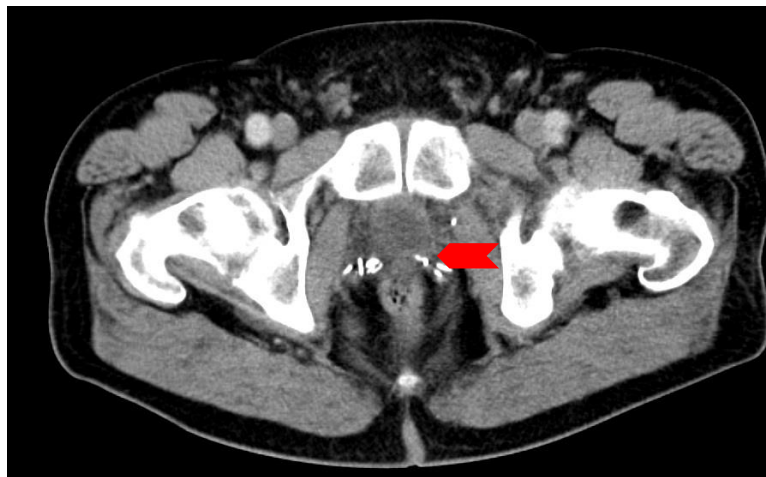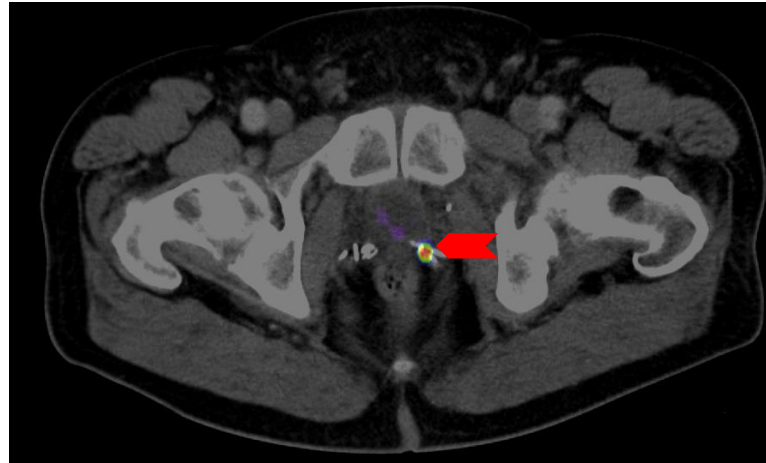
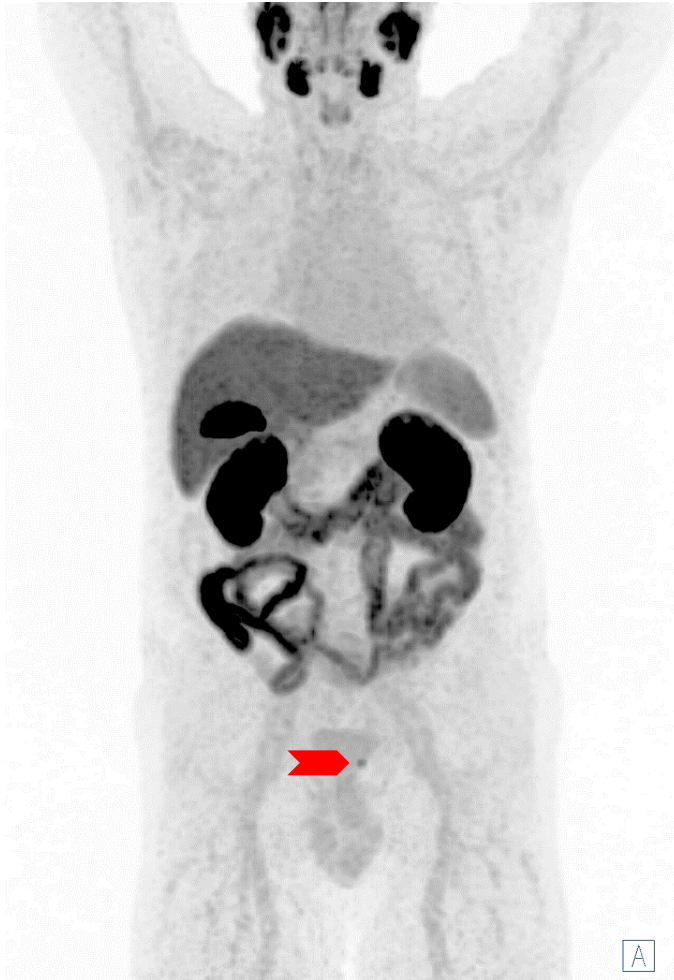
Restaging - Local Recurrence (Case 1)



- Please click on the video icon on the right side to open the video or scan the QR code on the left side with your QR app on your smart phone!



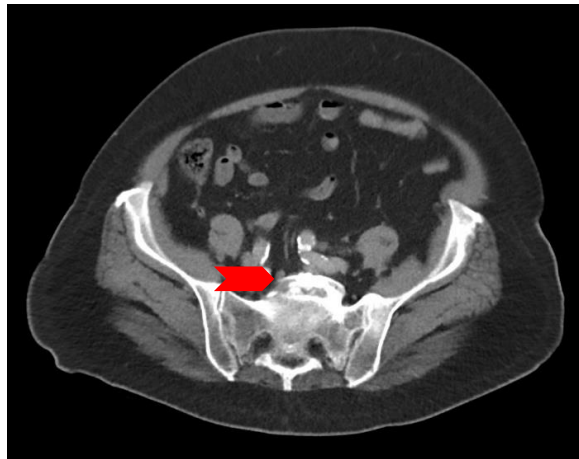
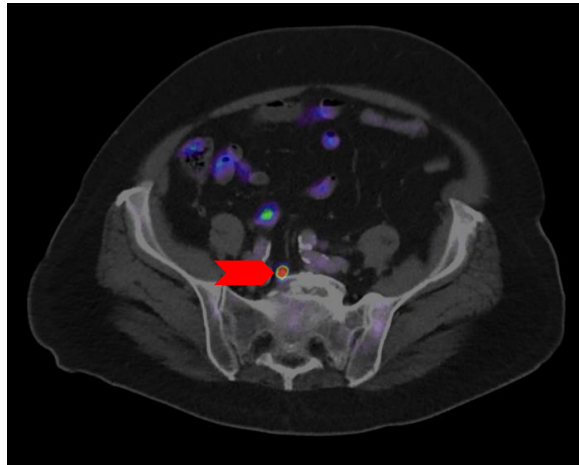
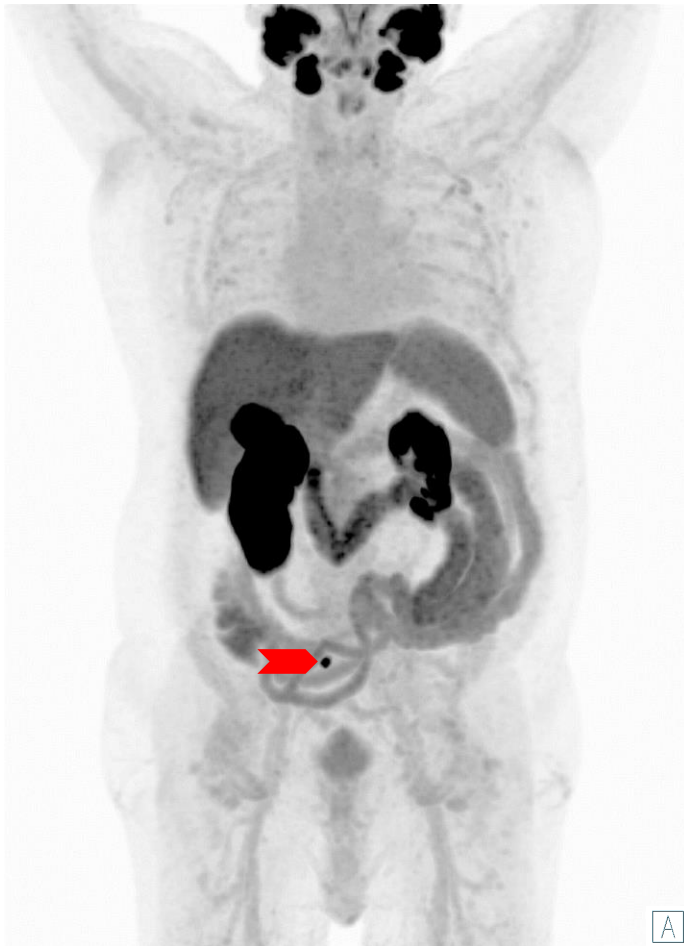
Restaging in Patients with Suspected Recurrence - Local Recurrence



- Gleason Score 3+3 = 6
- PSA recurrence (0.3 ng/ml) after radical prostatectomy
- Local recurrence with focal PSMA uptake was detected at the prostatectomy bed- close location of clips material

Images: University Hospital Essen, Department of nuclear medicine.

Restaging in Patients with Suspected Recurrence - Local Lymph Node Metastasis (Iliac)



- Iliac lymph nodes are one of the most common sites for (local) prostate cancer metastases
- However, these lymph node metastases are often not pathologically enlarged, especially in early stages of the disease they can be difficult to detect.
- [^{18}F]PSMA-1007 increases the detection rate of these lymph node metastases and significantly improves staging.
- The accuracies for detecting lymph node metastases are described for diameters as small as 1mm (median 5mm). [1]
- PSA recurrence (PSA. 0.93 ng/ml) after radical prostatectomy. Right presacral small lymph node metastasis with 5 mm of diameter was detected (red arrow)


Images: University Hospital Essen, Department of nuclear medicine.

[1] Giesel FL et al. Eur J Nucl Med Mol Imaging. 2017 Apr;44(4):678-688.

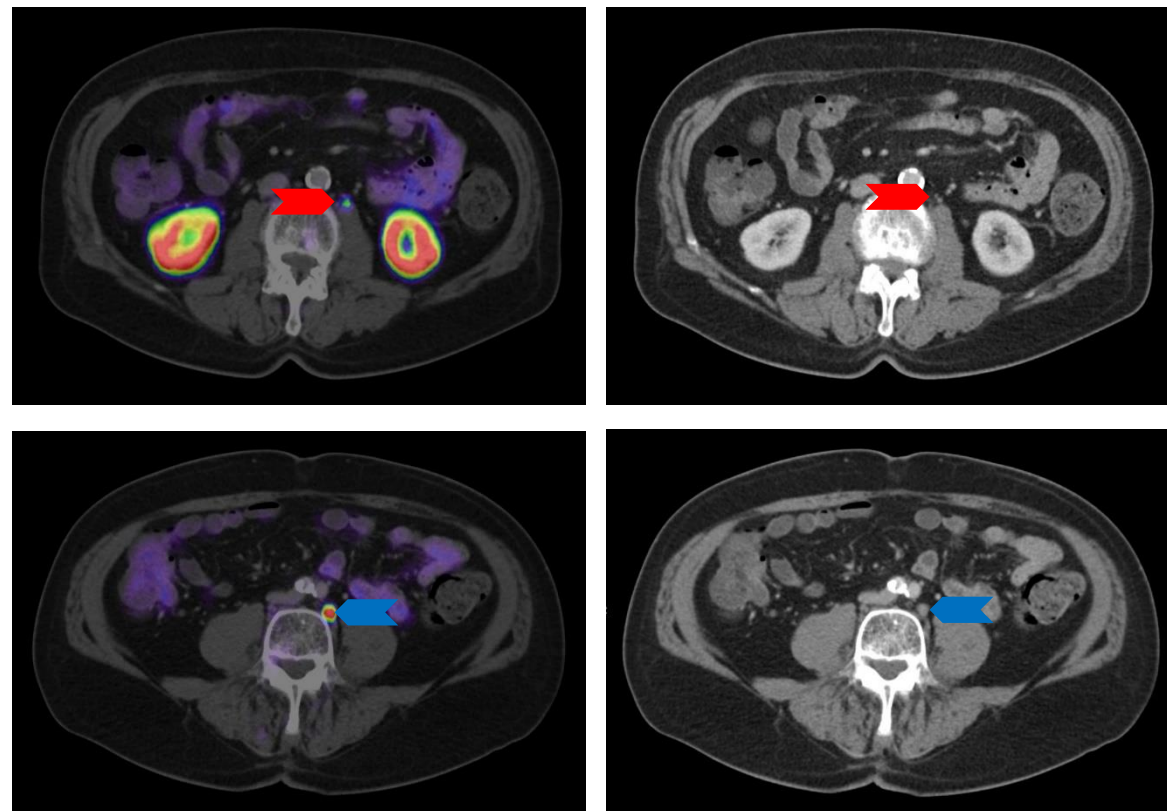
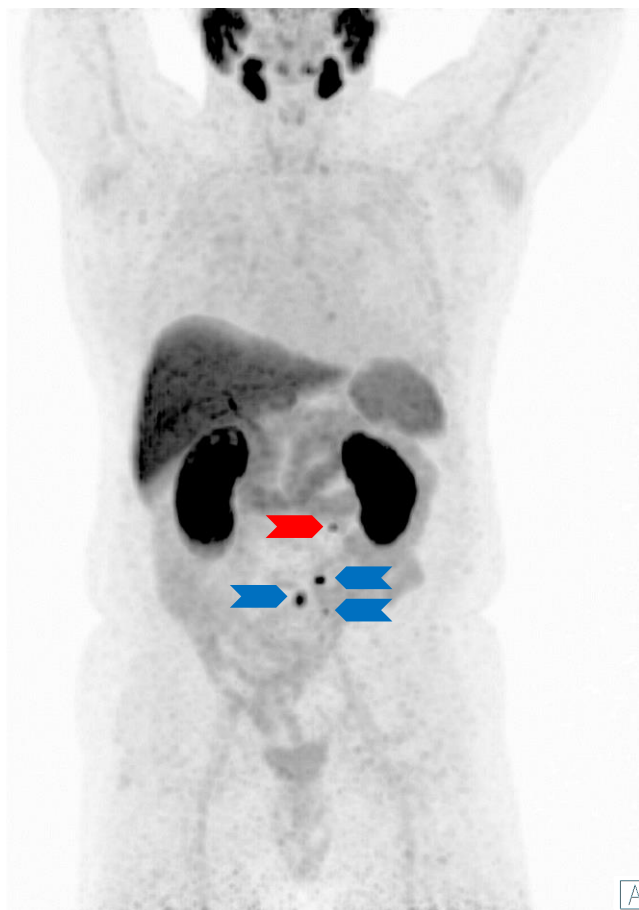Restaging - Local Lymph Node Metastasis (Iliac)



- Please click on the video icon on the right side to open the video or scan the QR code on the left side with your QR app on your smart phone!



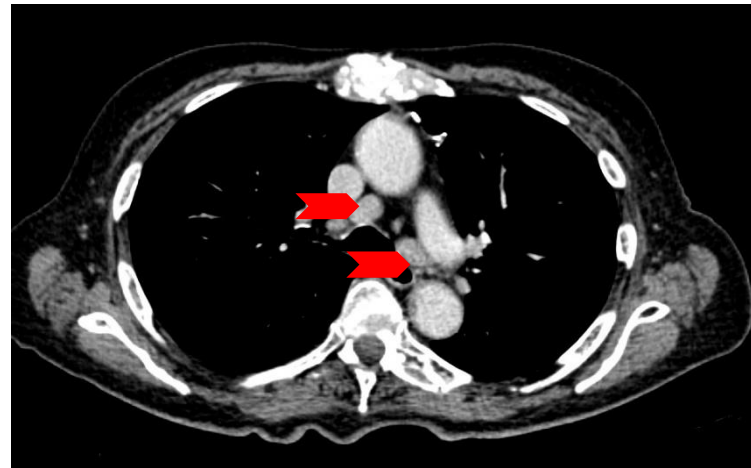
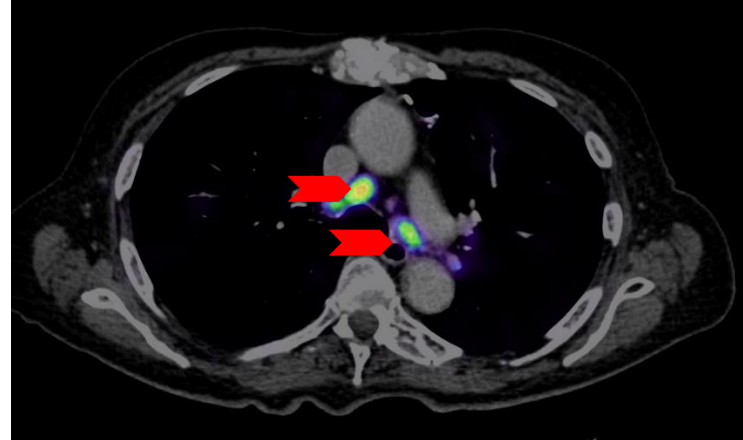
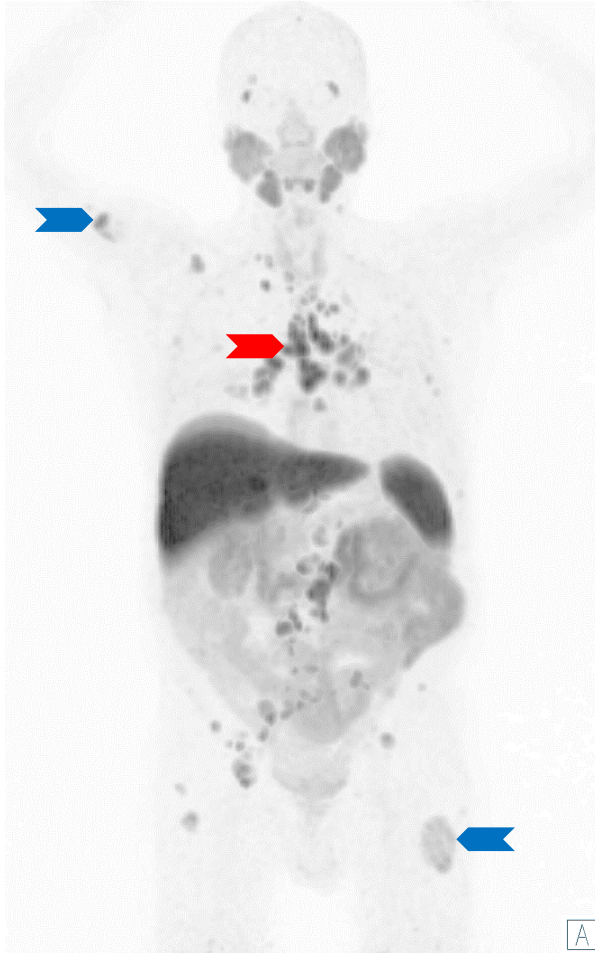
Restaging in Patients with Suspected Recurrence - Distant Lymph Node Metastases (Retroperitoneal)



- Biochemical Recurrence (BCR) after radical prostatectomy, salvage lymph node dissection and salvage pelvic radiotherapy.
- Retroperitoneal lymph node metastases with the diameter of 4-7 mm (Blue and red arrows)

Images: University Hospital Essen, Department of nuclear medicine.

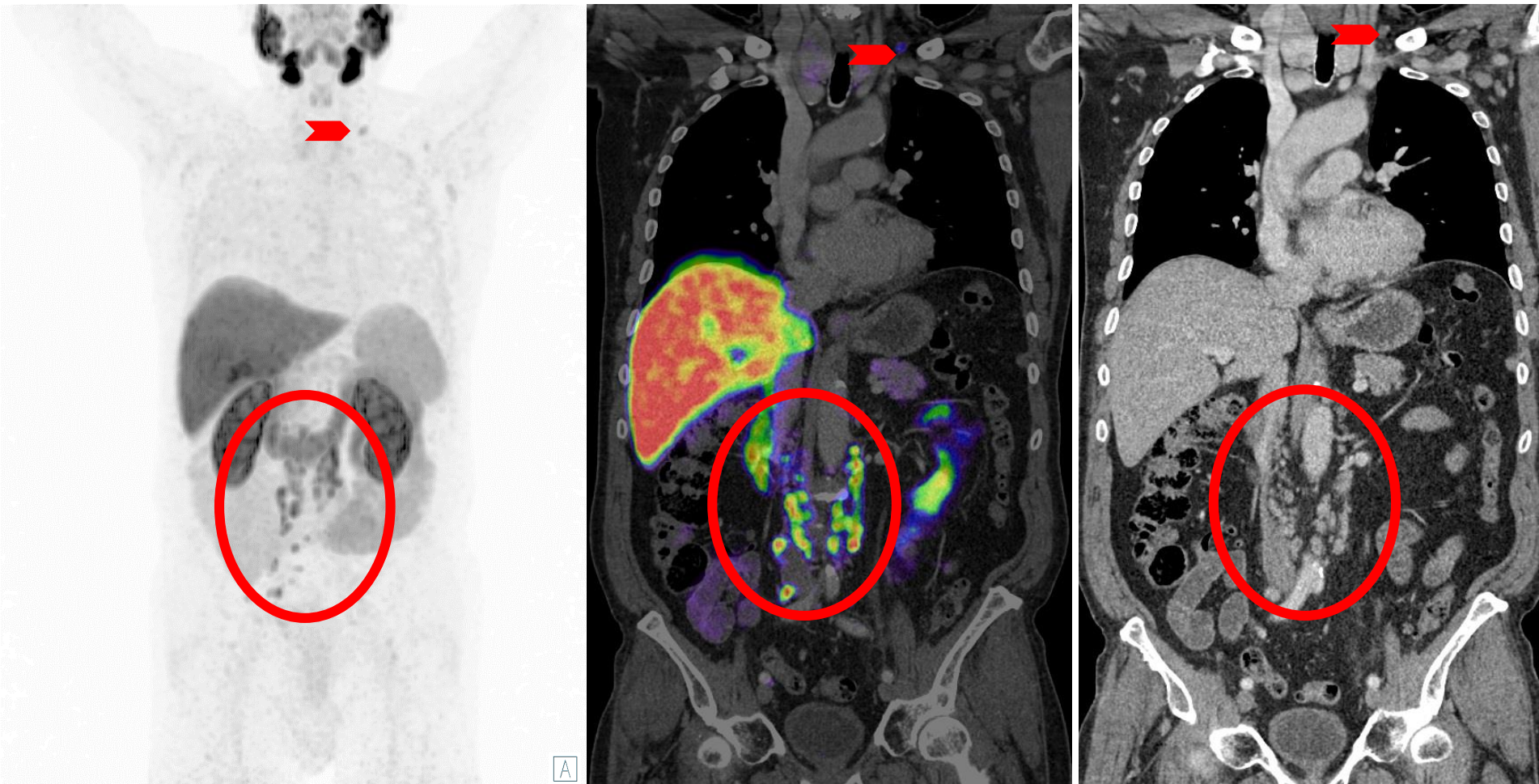
Restaging in Patients with Suspected Recurrence - Distant Lymph Node Metastases (Mediastinal)



- Thoracic lymph node metastases (red arrows) are rather rare
- These usually occur at an advanced stage in the presence of many other metastases
 - Multiple bone metastases are also present (exemplary blue arrows)
- Thoracic lymph node metastases should not be confused with Sarcoidosis

Images: University Hospital Essen, Department of nuclear medicine.

Restaging in Patients with Suspected Recurrence - Distant Lymph Node Metastases (Supraclavicular-Virchow's Lymph Node)




- Single left supraclavicular lymph node metastasis (red arrow)
- M1a - supradiaphragmatic localization
- Multiple lymph node metastases retroperitoneal (red circle)

Images: University Hospital Essen, Department of nuclear medicine.

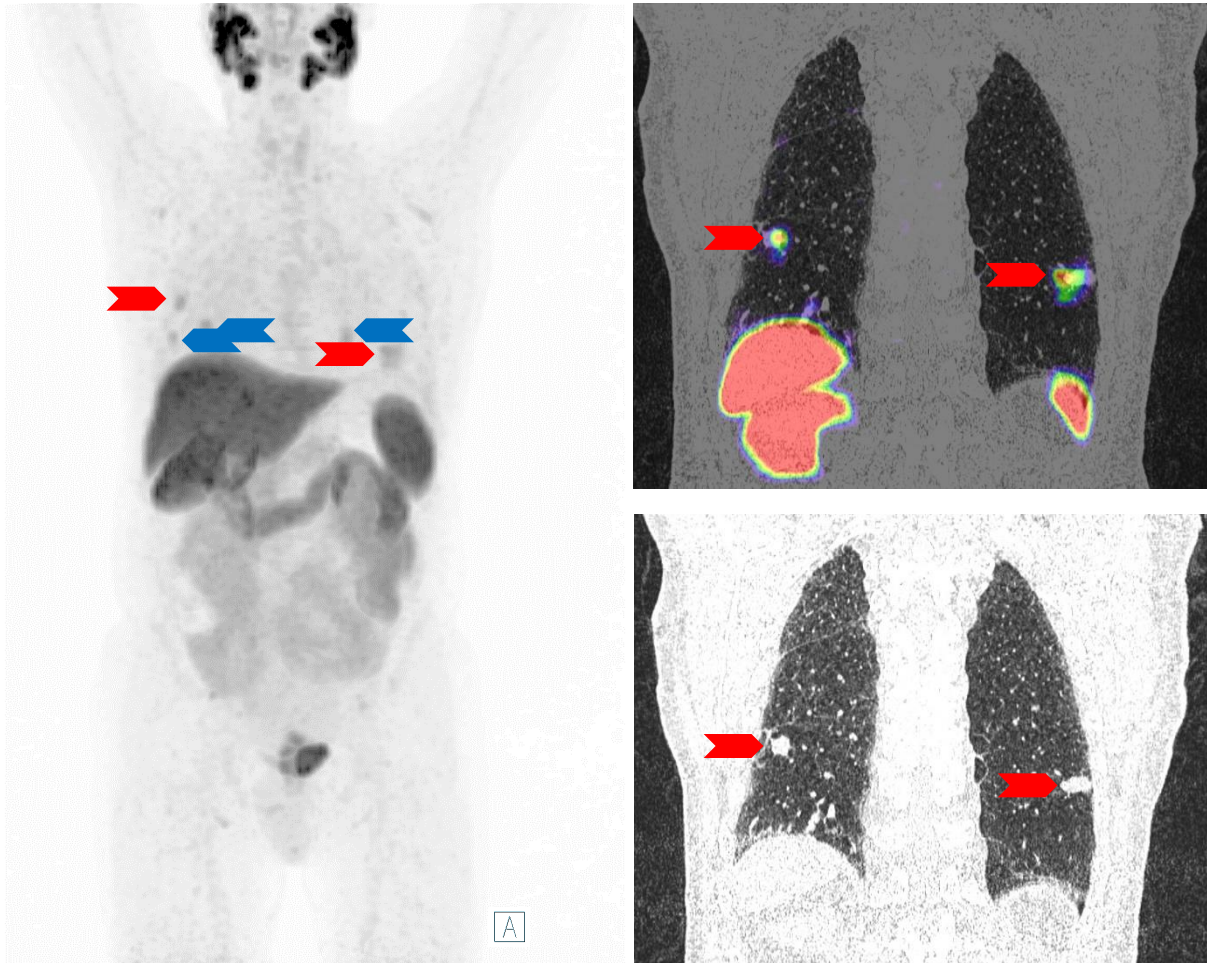
Restaging - Distant Lymph Node Metastases (Supraclavicular-Virchow`s Lymph Node)



- Please click on the video icon on the right side to open the video or scan the QR code on the left side with your QR app on your smart phone!



Restaging in Patients with Suspected Recurrence - Lung Metastases (Case 1)




Images: University Hospital Essen, Department of nuclear medicine.

- Although uncommon, lung metastases may still occur in patients with prostate cancer and should not be excluded as a possibility.
- When evaluating the possibility of pulmonary metastases versus a second malignancy that is also PSMA-positive, a thorough examination of the individual case is crucial.
- Due to the acquisition of PET images in respiratory mid-position, respiratory or motion artifacts may occur, which can manifest in the form of comet tails or falsely positive additional tumors. Use all available image series for better assignment of tracer uptake.
- This patient has multiple lung metastases (red arrows in the corresponding CT and fusion images), as well as additional lung metastases (blue arrows).

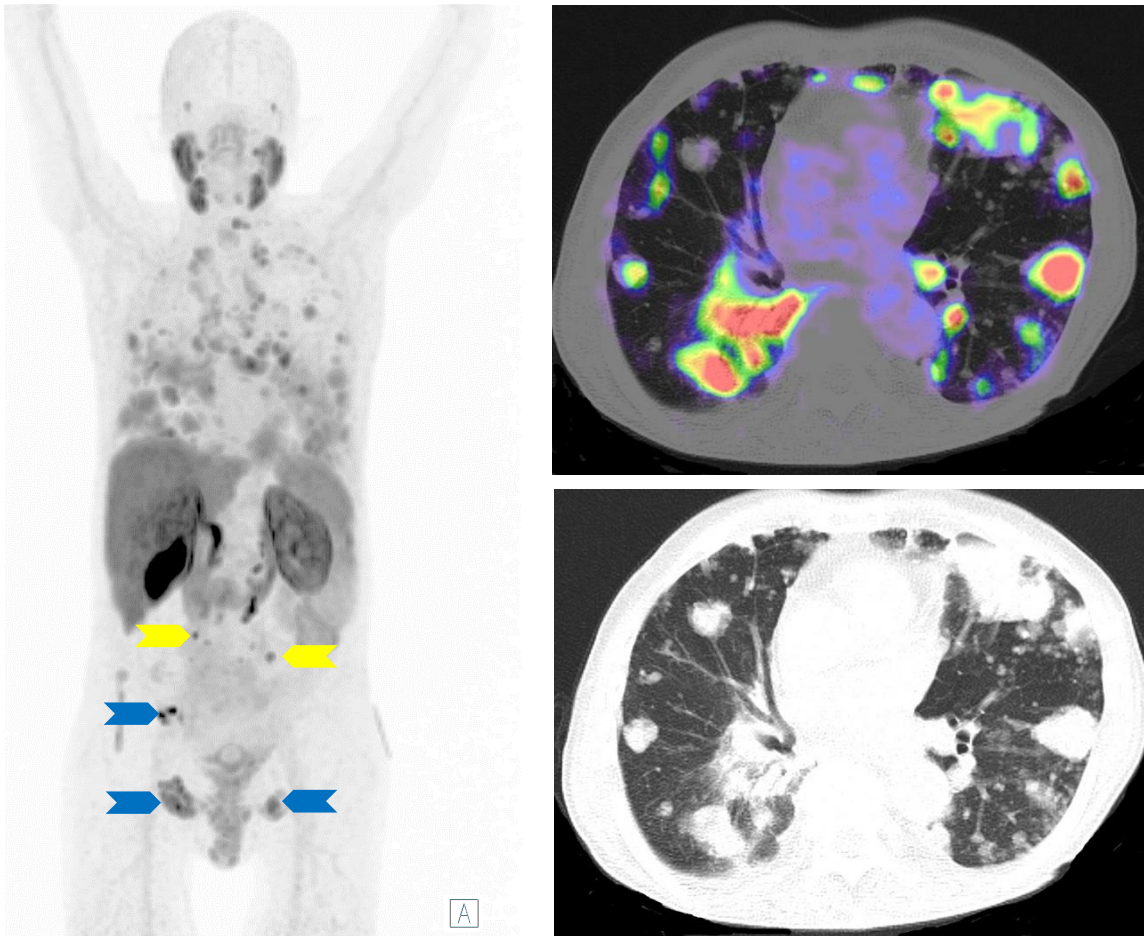
Restaging - Lung Metastases (Case 1)



- Please click on the video icon on the right side to open the video or scan the QR code on the left side with your QR app on your smart phone!



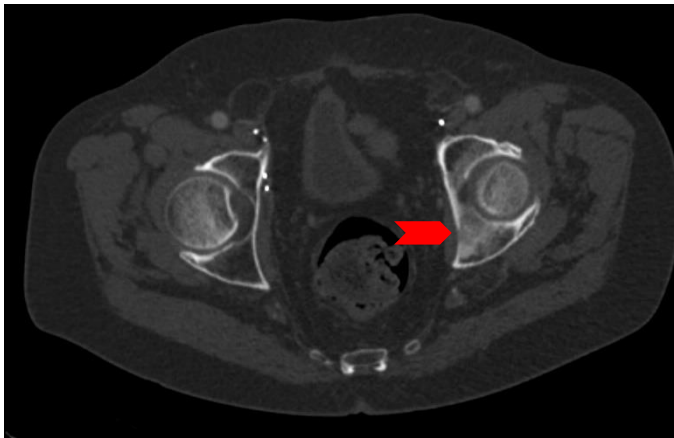
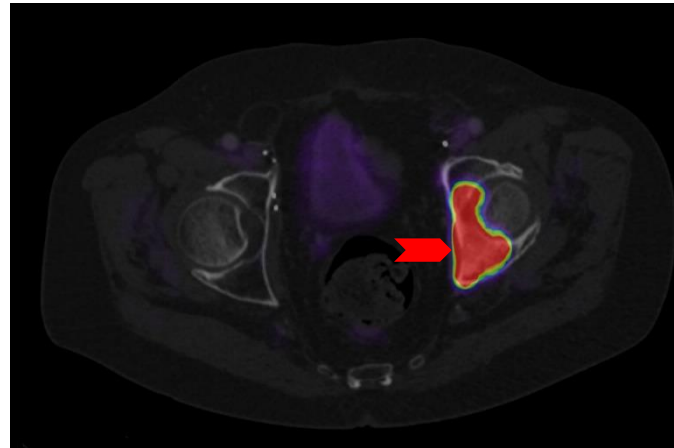
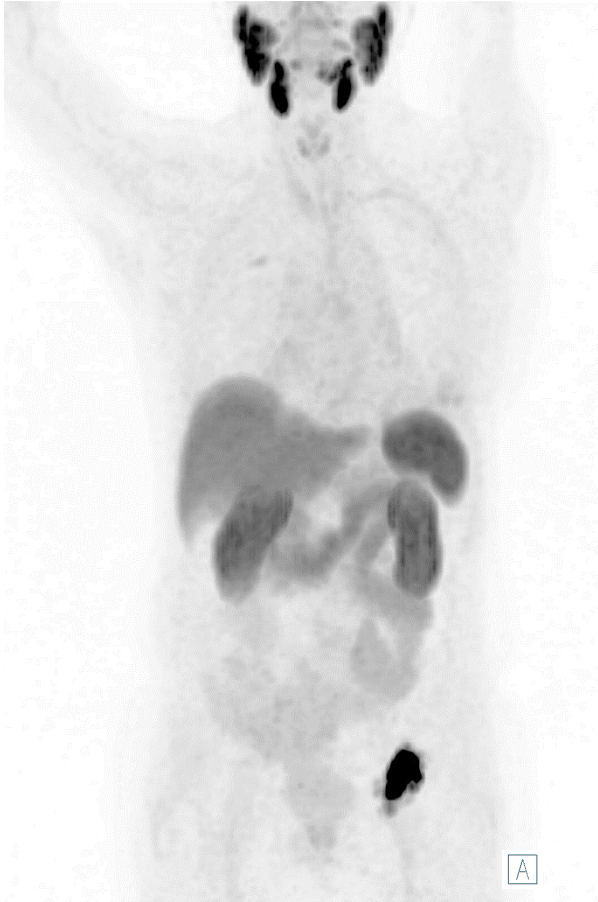Restaging in Patients with Suspected Recurrence - Lung Metastases (Case 2)



- Late-stage prostate-cancer patient with the rare manifestation of disseminated lung metastases (whole thoracic area)
- In addition, multiple bone metastases (exemplary blue arrows) as well as lymphonodular metastases (exemplary yellow arrows) are also present.

Images: University Hospital Essen, Department of nuclear medicine.

Restaging in Patients with Suspected Recurrence - Single Bone Metastasis




- Typically, bone metastases from prostate cancer present an osteoblastic (hyperdense) appearance and are therefore easily detectable in morphological imaging such as CT.
- Compared to CT and bone scintigraphy, the utilization of [^{18}F]PSMA-1007 improves the detection sensitivity.

Images: University Hospital Essen, Department of nuclear medicine.

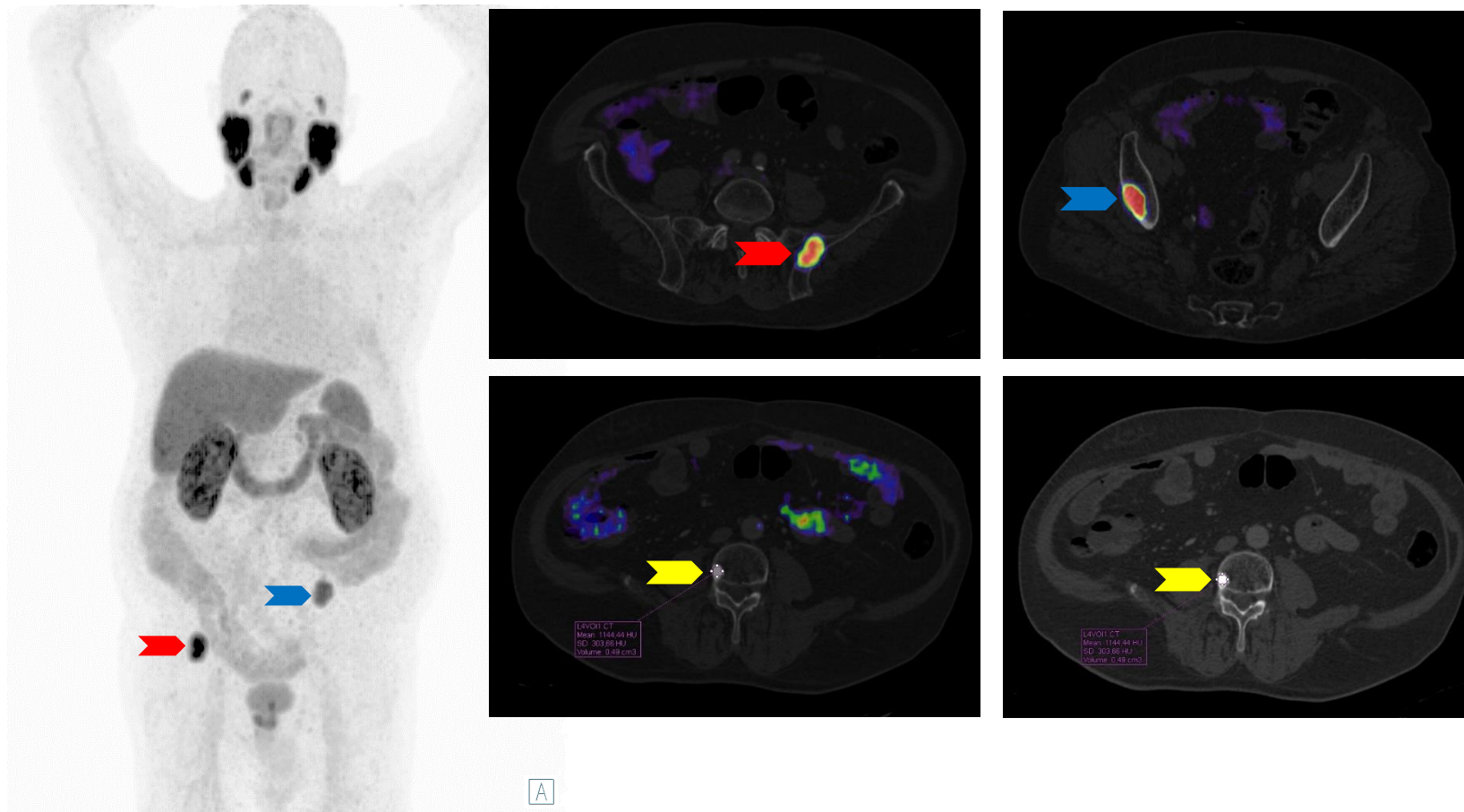
Restaging - Single Bone Metastasis



- Please click on the video icon on the right side to open the video or scan the QR code on the left side with your QR app on your smart phone!



Restaging in Patients with Suspected Recurrence - Oligometastatic Bone Metastases

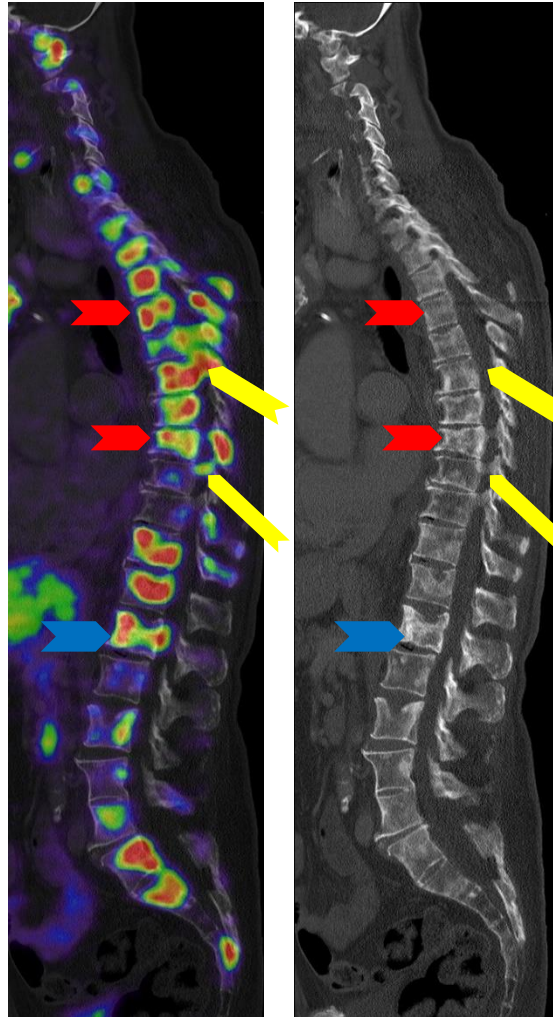
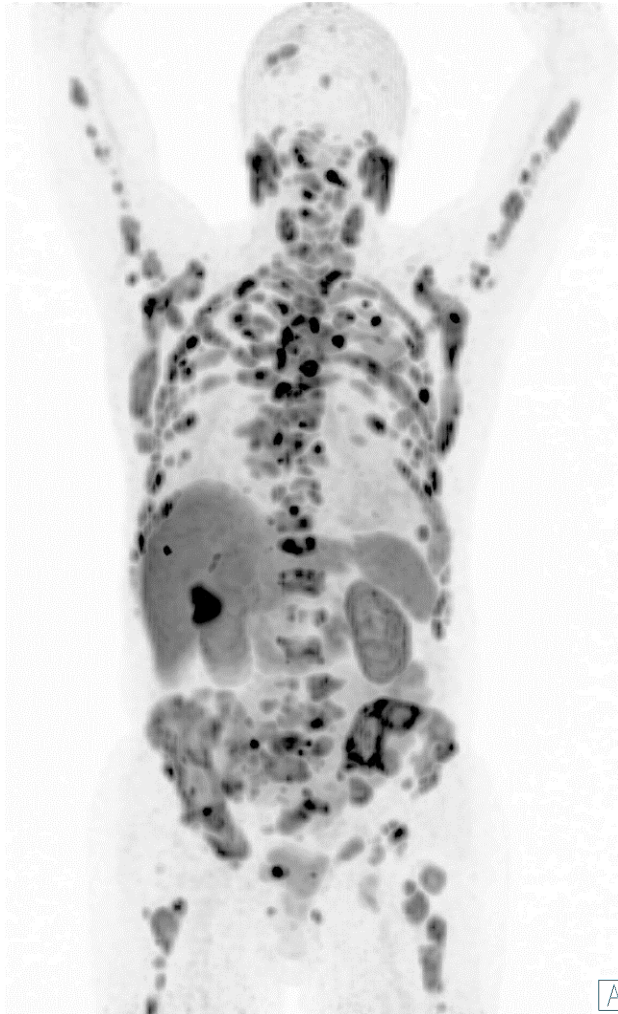

- Bone metastases (red and blue arrows) vs. Bone Island (yellow arrow)
Differential Diagnosis
- Bone metastasis: focal uptake with mostly sclerosis, however it can be with also lytic or mixed type. Mean attenuation of the sclerotic lesion is lower than 885 HU [1]
- Bone island: typical paint brush edges without relevant PSMA uptake. Mean attenuation of the lesion is higher than 885 HU [1]

Images: University Hospital Essen, Department of nuclear medicine.

[1] Ulano A et al. AJR Am J Roentgenol. 2016 Aug;207(2):362-8

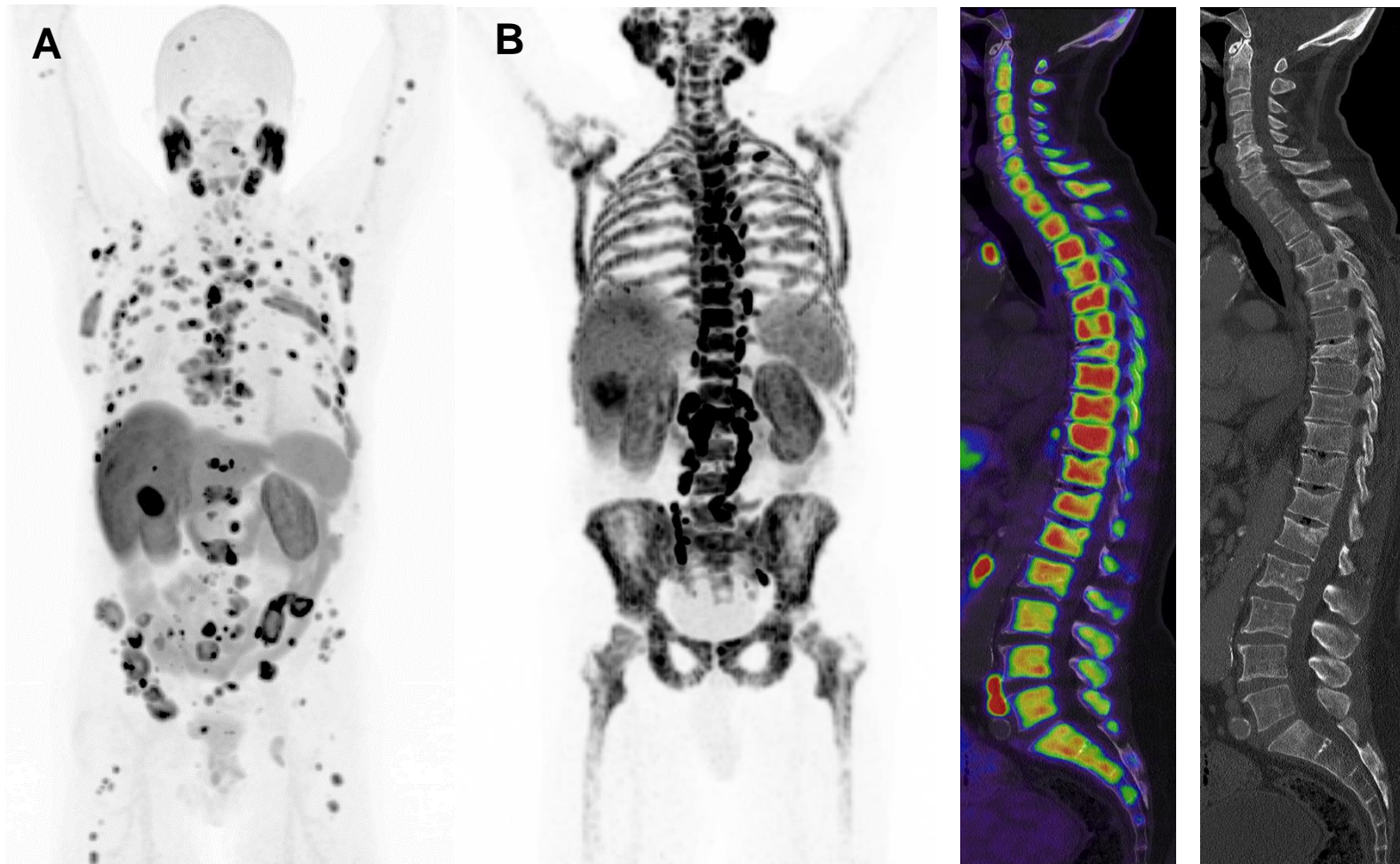
Restaging in Patients with Suspected Recurrence - Disseminated Bone Metastases



- Disseminated bone metastases with varying intensity of PSMA-Expression
- Important findings:
 - Multiple compression fractures (red arrows)
 - Lytic metastasis of the first lumbar vertebra with involvement of more than 50 percent of the vertebral body (blue arrow)
 - Intraspinal tumor manifestations (yellow arrows)

Images: University Hospital Essen, Department of nuclear medicine.

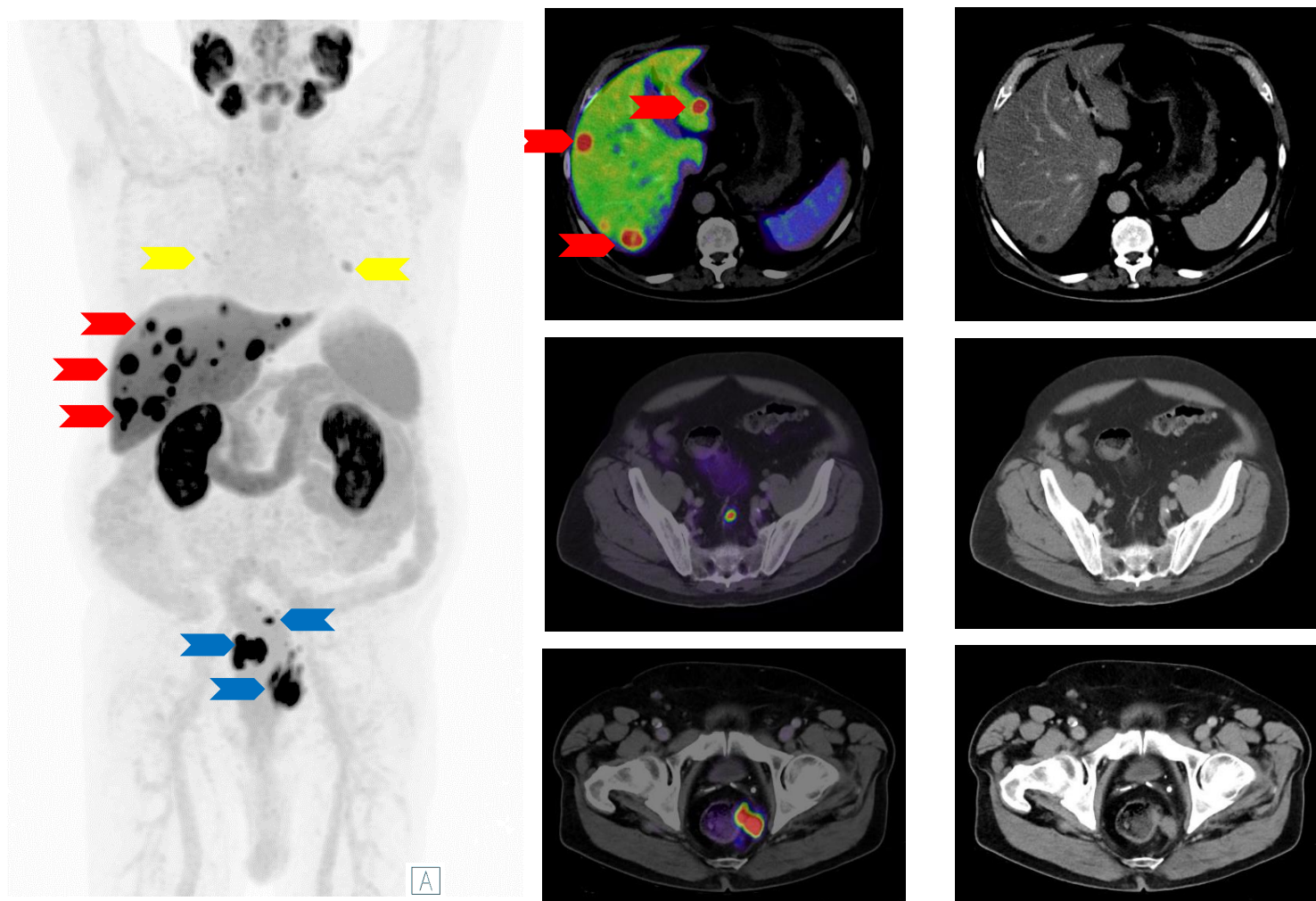
Restaging in Patients with Suspected Recurrence - Diffuse Bone Marrow Infiltration



Images: University Hospital Essen, Department of nuclear medicine.

- Comparison of two patients with different manifestations of bone metastases:
 - A - Disseminated bone metastasis
 - B - Diffuse bone-marrow infiltration (DMI)
- Disseminated bone metastases are characterized by multiple focal areas of tracer uptake, while diffuse bone-marrow infiltration is characterized by partial to complete involvement of a single bone segment or the entire skeletal system.
- B - The entire skeletal system of the patient exhibits tumor infiltration, similar to the image obtained of a physiological whole-body bone scan.
- Diffuse marrow infiltration is associated with poorer outcomes and lower overall survival rates.

Restaging in Patients with Suspected Recurrence - Liver Metastases

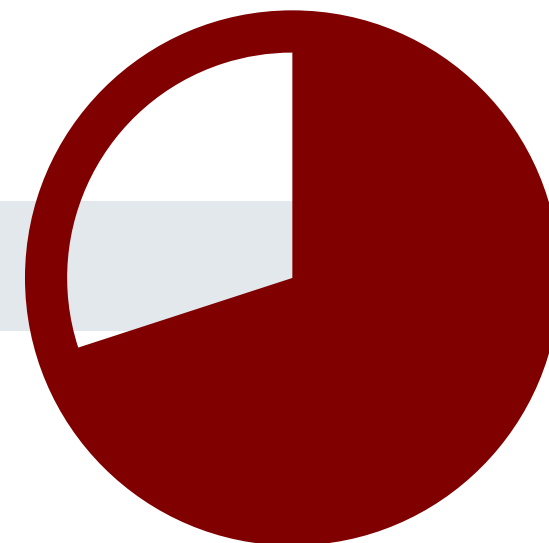


Images: University Hospital Essen, Department of nuclear medicine.

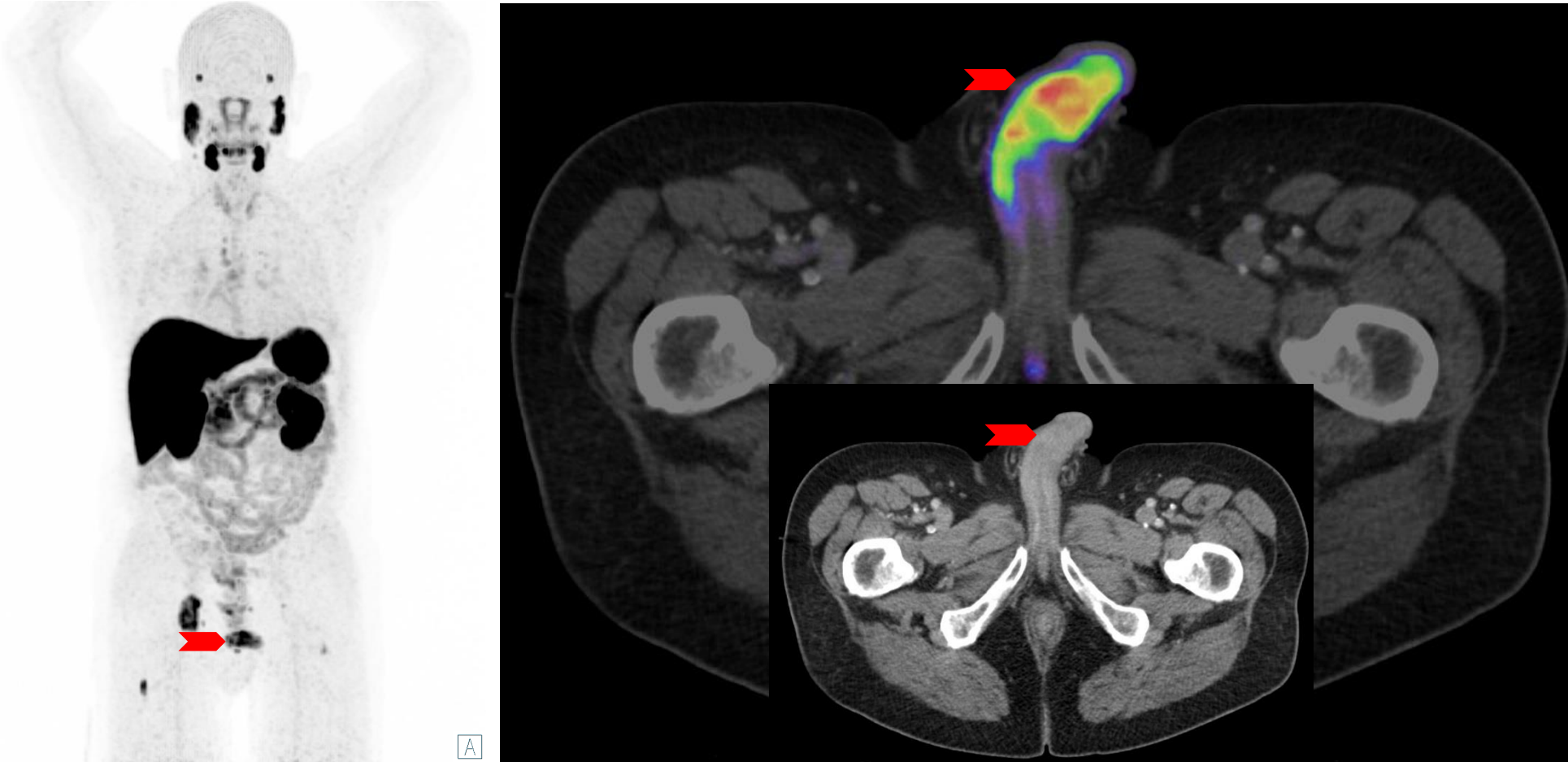
- Prostate cancer has the worst prognosis when found in the liver compared to other metastatic sites.
- These metastatic nodules display a therapy resistance in the liver pro-metastatic microenvironment; the resistance appears to be conferred by both dormancy and independent of dormancy when the nodules emerge [1]
- Disseminated bi-lobar liver metastases (exemplary red arrows).
- Multiple pararectal lymph node metastases, some with suspected infiltration of the rectum (blue arrows).
- Additionally, there is suspicion of pulmonary and/or pleural metastases (yellow arrows).

[1] Ma B, et al. Semin Cancer Biol. 2021 Jun;71:2-9.

Rare Locations of Metastases



Rare Location of Metastases - Penis Metastasis

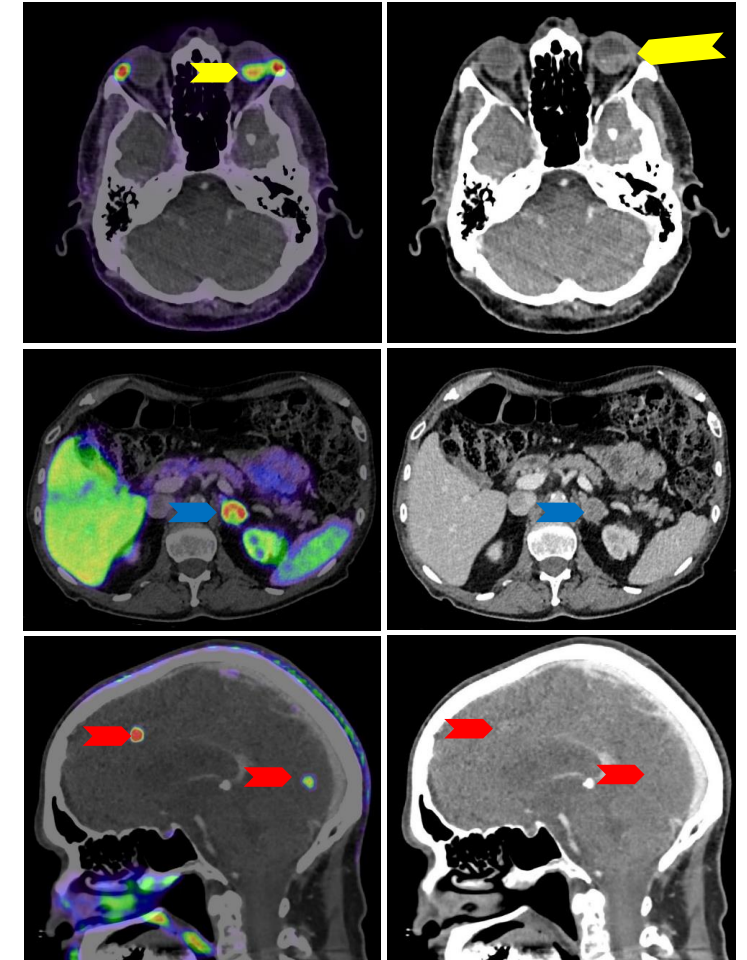
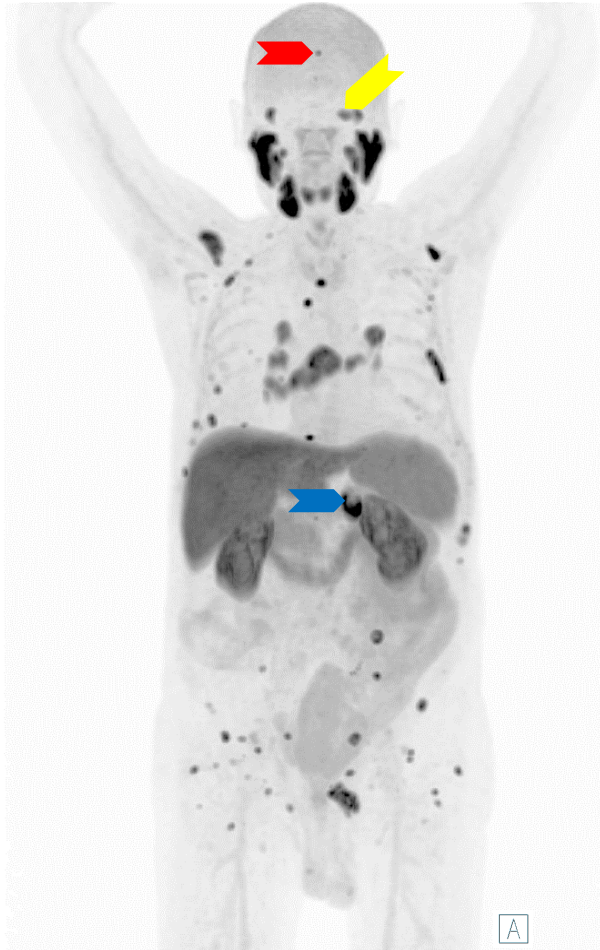


- Penile metastases are a rare form of metastasis of prostate cancer (red arrow).
- Many other metastases are present in this case, including bone and lymph node metastases.
- They often show contrast enhancement in the corresponding CT scan.
- It is particularly important to differentiate these metastases from urine activity or contamination.

Images: University Hospital Essen, Department of nuclear medicine.

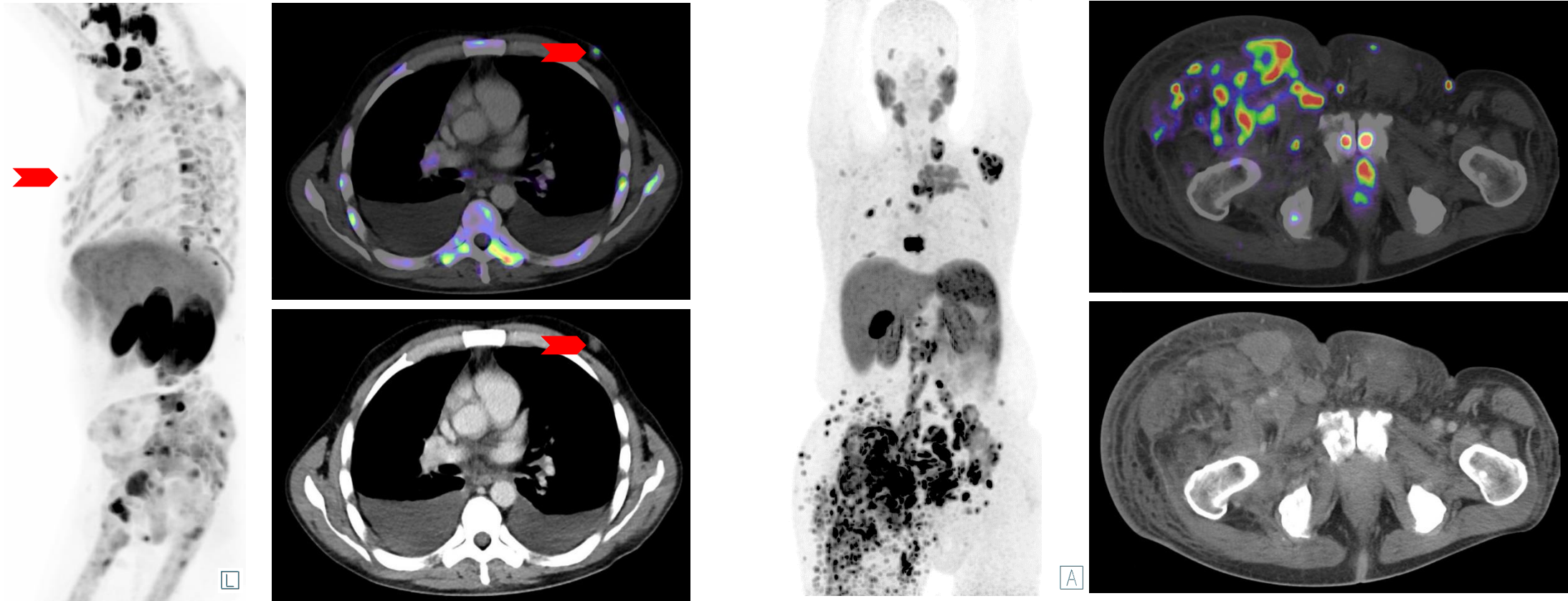
Rare Location of Metastases - Retinal, Adrenal and Meningeal Metastases

- This case shows a rather atypical distribution pattern of metastases:
 - Retinal metastasis (yellow arrow)
 - Adrenal metastasis (blue arrow)
 - Meningeal metastases (red arrows)
- In such cases, a histopathological confirmation to rule out a second malignancy may be useful.
 - A biopsy of the retinal metastasis in this patient revealed evidence of a prostate cancer metastasis and ruled out a second malignancy.



Images: University Hospital Essen, Department of nuclear medicine.

Rare Location of Metastases - Retroareolar, cutaneous, subcutaneous and muscle metastases

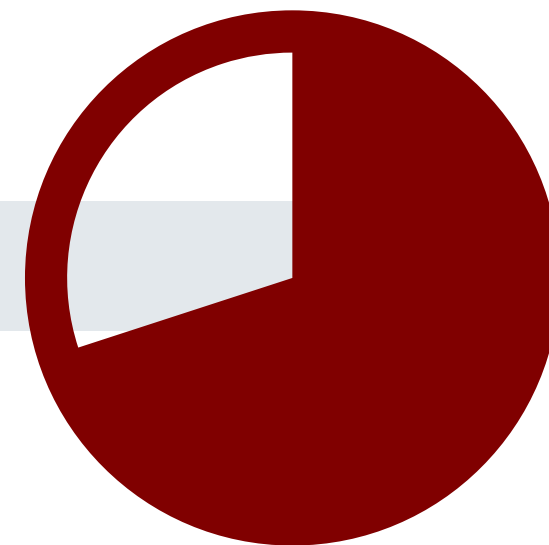


■ Left retroareolar mammary metastasis (red arrow)

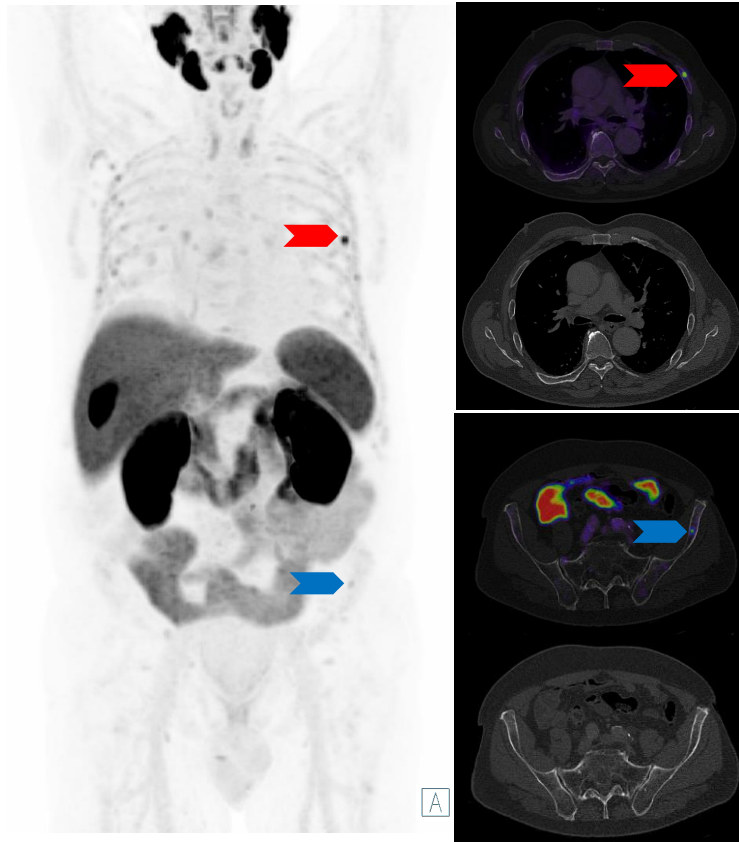
■ Multiple cutaneous, subcutaneous and muscle metastases. Possible lymphatic obstruction and secondary lymphedema of the right lower limb

Images: University Hospital Essen, Department of nuclear medicine.

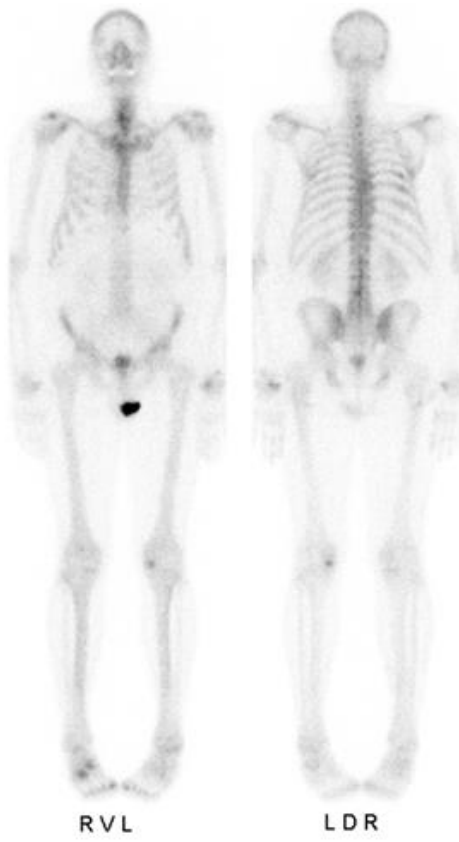
Unspecific Bone Uptake
Specific Bone Uptake



Unspecific Bone Uptake



[¹⁸F]PSMA-1007 PET/CT



Bone Scan (same patient)

- Unspecific bone uptake (UBU) is defined as mid to moderate focal uptake without CT/MRI correlation [1]
 - Usually occurring in ribs (red arrows) and pelvis blue arrows)
- Rarely represent bone metastases of a prostate cancer
- Possible Explanations for Bone Uptake [2]:
 - Activated granulocytes in bone marrow
 - Focal bone marrow islands
 - Radiologically undetected other bone lesions
 - Unconjugated Fluorine → rather diffuse
 - Myeloproliferative diseases → rather diffuse
- Diagnostic recommendations:
 - UBU with uptake < spleen and absence of other metastases → benign
 - UBU with uptake > spleen and absence of other metastases → equivocal to positive (further investigation can be suggested, depending on individual risk)
 - UBU with uptake > spleen and presence of other metastases → positive


[1] Arnfield EG et al. Eur J Nucl Med Mol Imaging. 2021 Dec;48(13):4495-4507

[2] Seifert R et al. J Nucl Med. 2023; 64(5): 738-743

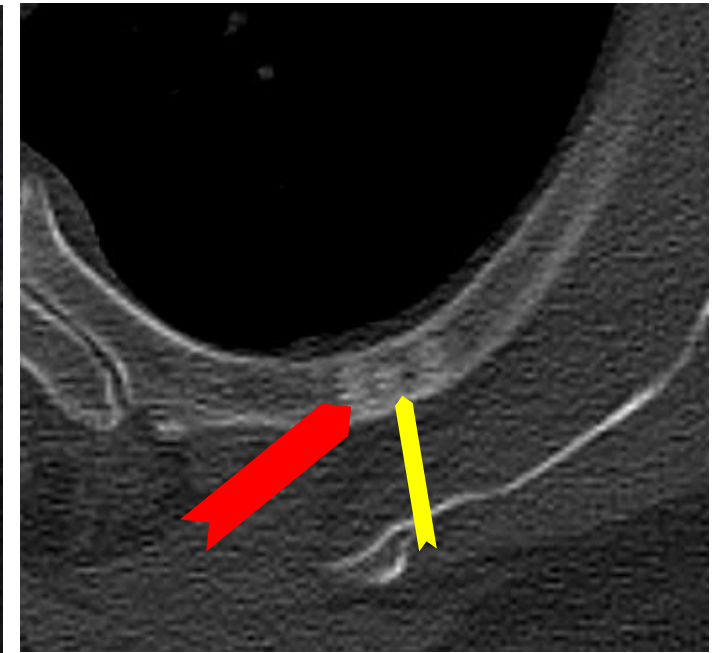
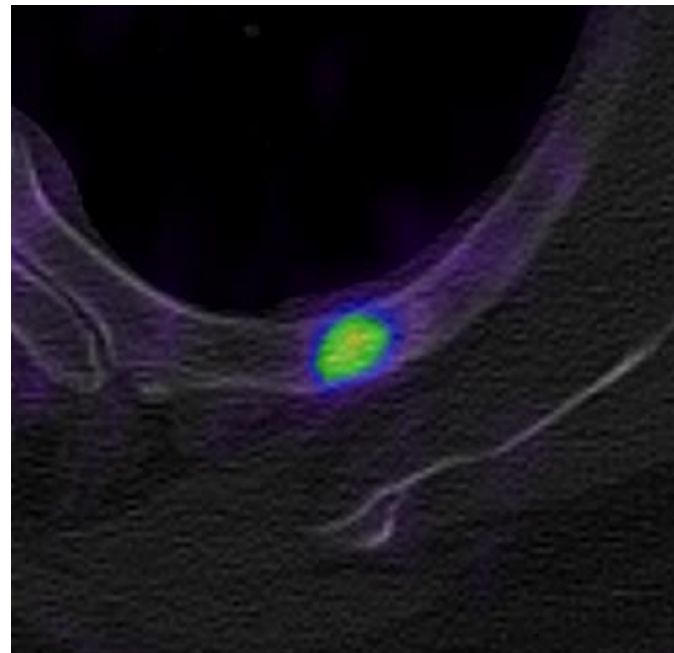
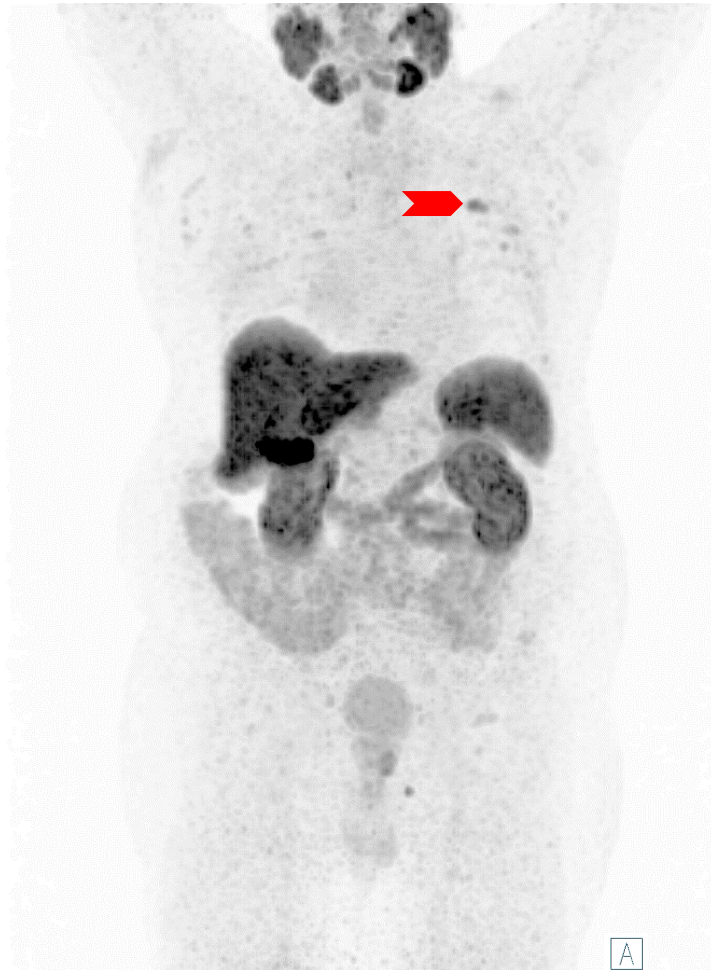
Unspecific Bone Uptake



- Please click on the video icon on the right side to open the video or scan the QR code on the left side with your QR app on your smart phone!



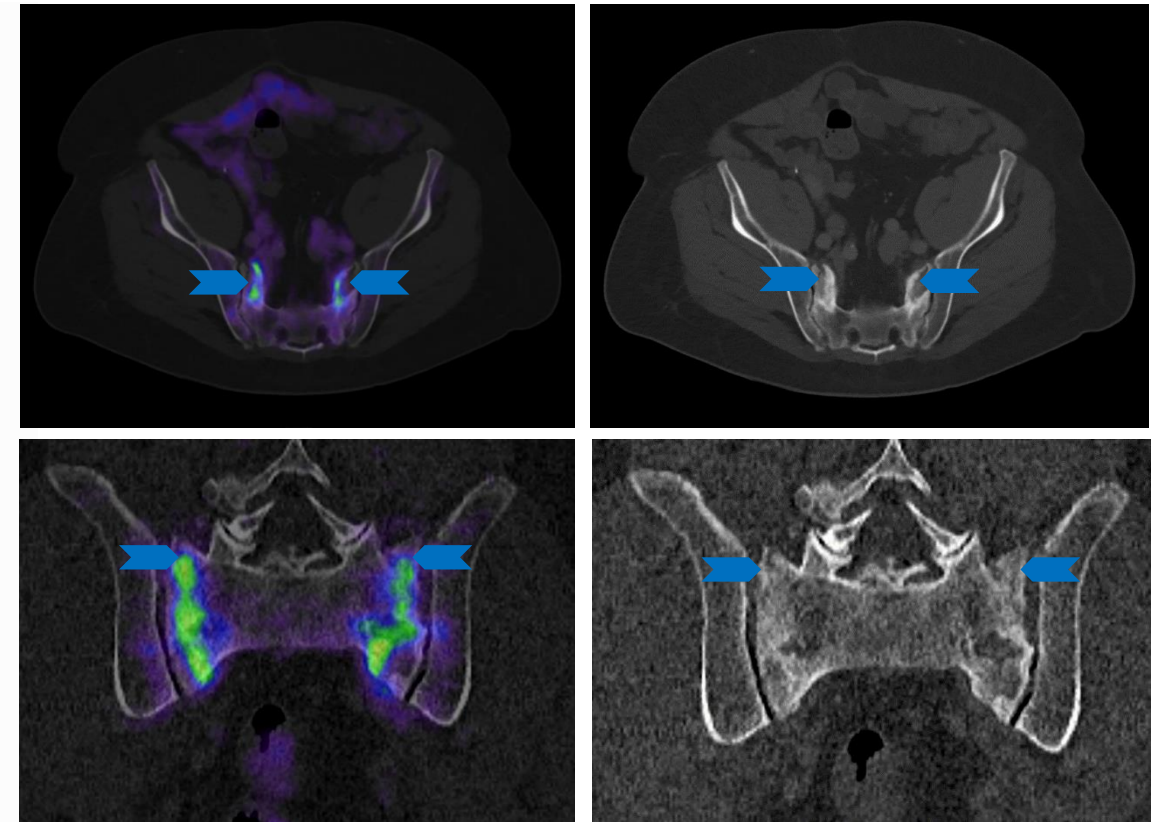
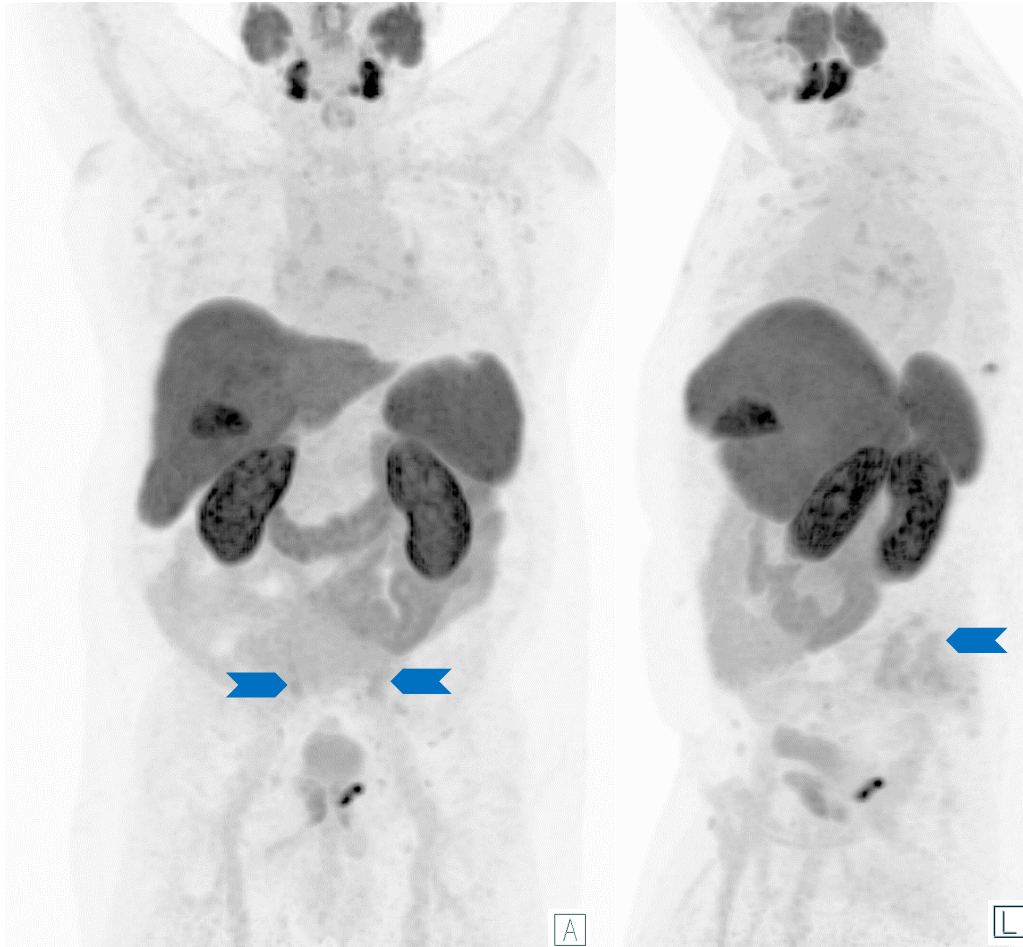
Specific Bone Uptake - Osteoid Osteoma



- < 2 cm bone lesion with central sclerosis, called nidus (yellow arrow), peripheral reactive sclerosis (red arrow) → Typical for osteoid osteoma
- Further investigation depending on individual risk factors can be suggested (such as MRI)

Images: University Hospital Essen, Department of nuclear medicine.

Specific Bone Uptake - Therapy Related False Positives

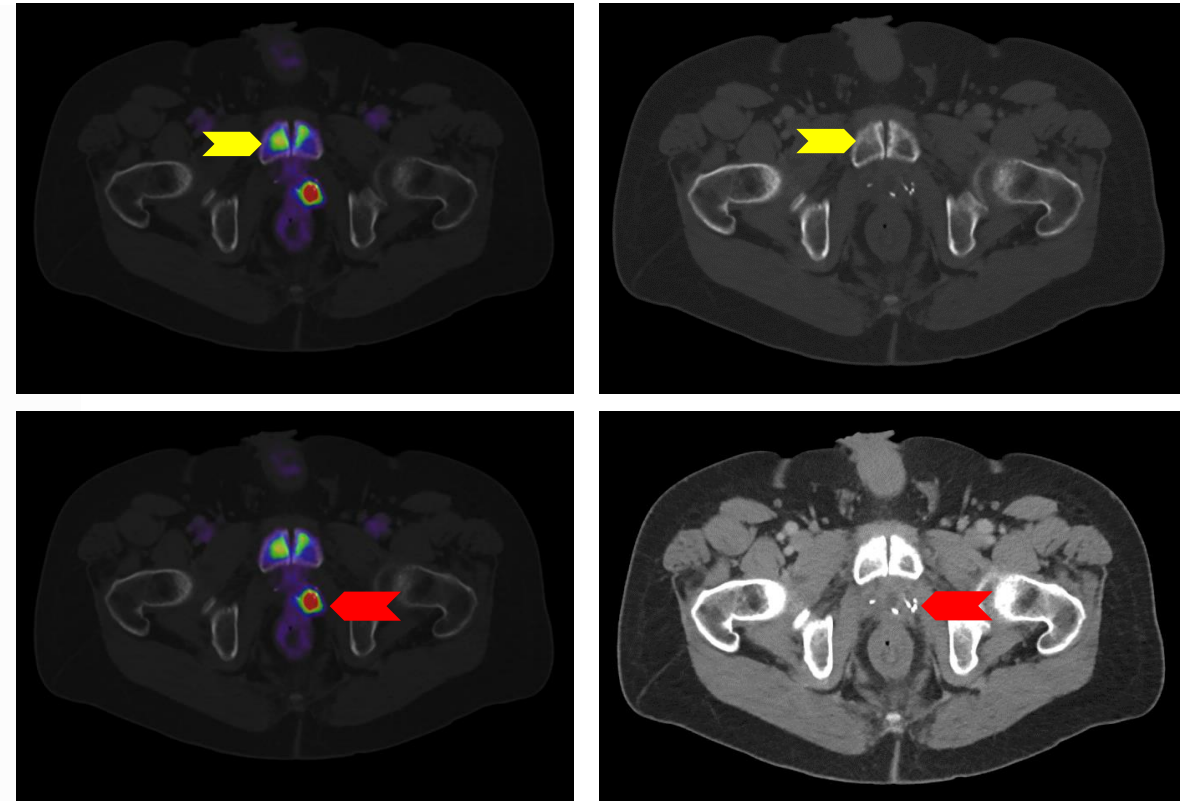
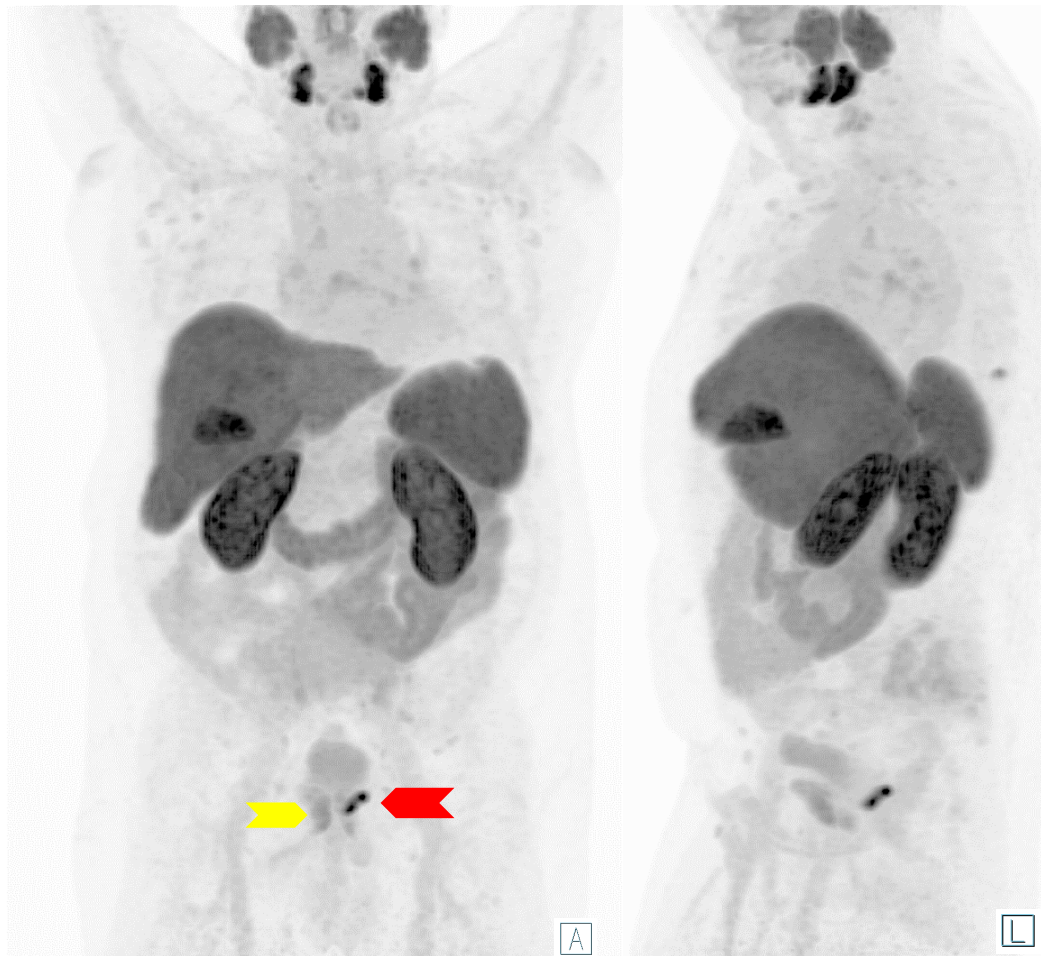


■ History of pelvic radiotherapy may cause symphysis and sacral insufficiency fracture (blue arrows)

■ Both present a low to moderate PSMA expression / Uptake

Images: University Hospital Essen, Department of nuclear medicine.

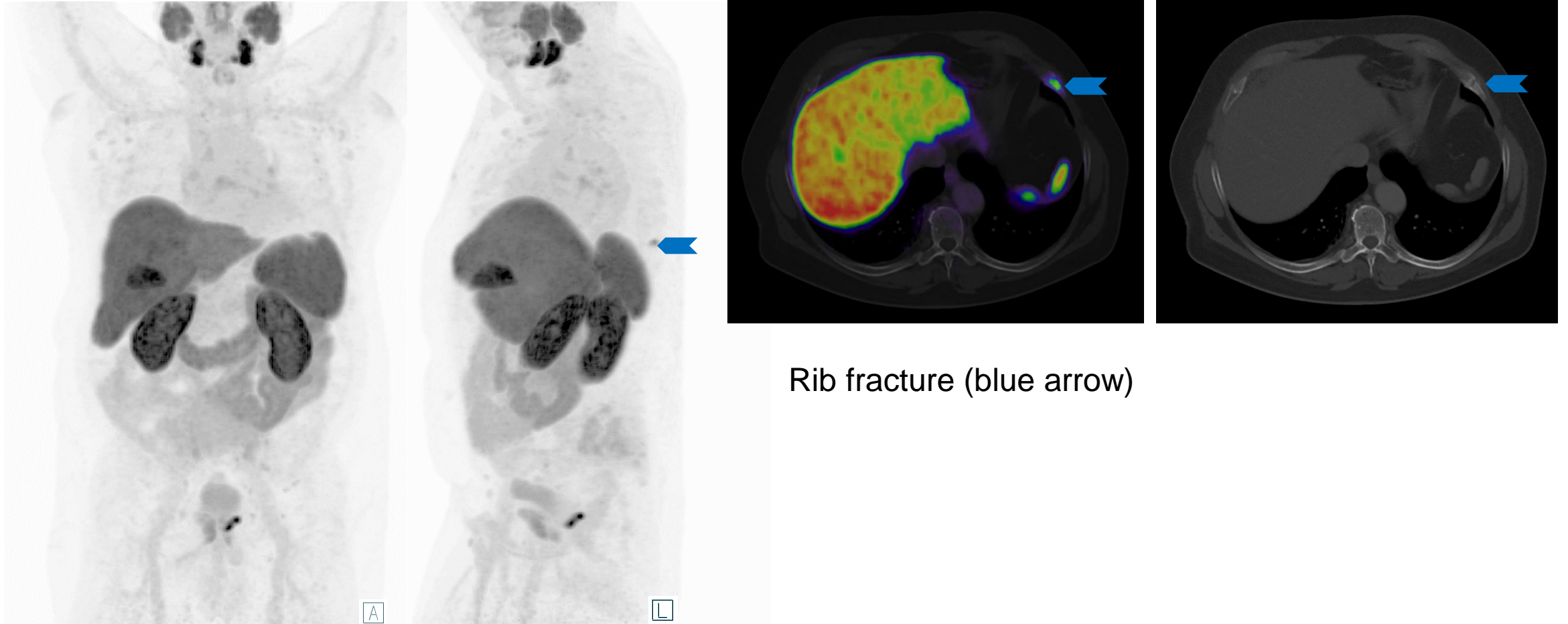
Specific Bone Uptake - Therapy Related False Positives



- History of pelvic radiotherapy may cause symphysis and sacral insufficiency fracture (yellow arrows)
 - Both present a low to moderate PSMA expression / Uptake
- Prostate cancer recurrence (red arrows)

Images: University Hospital Essen, Department of nuclear medicine.

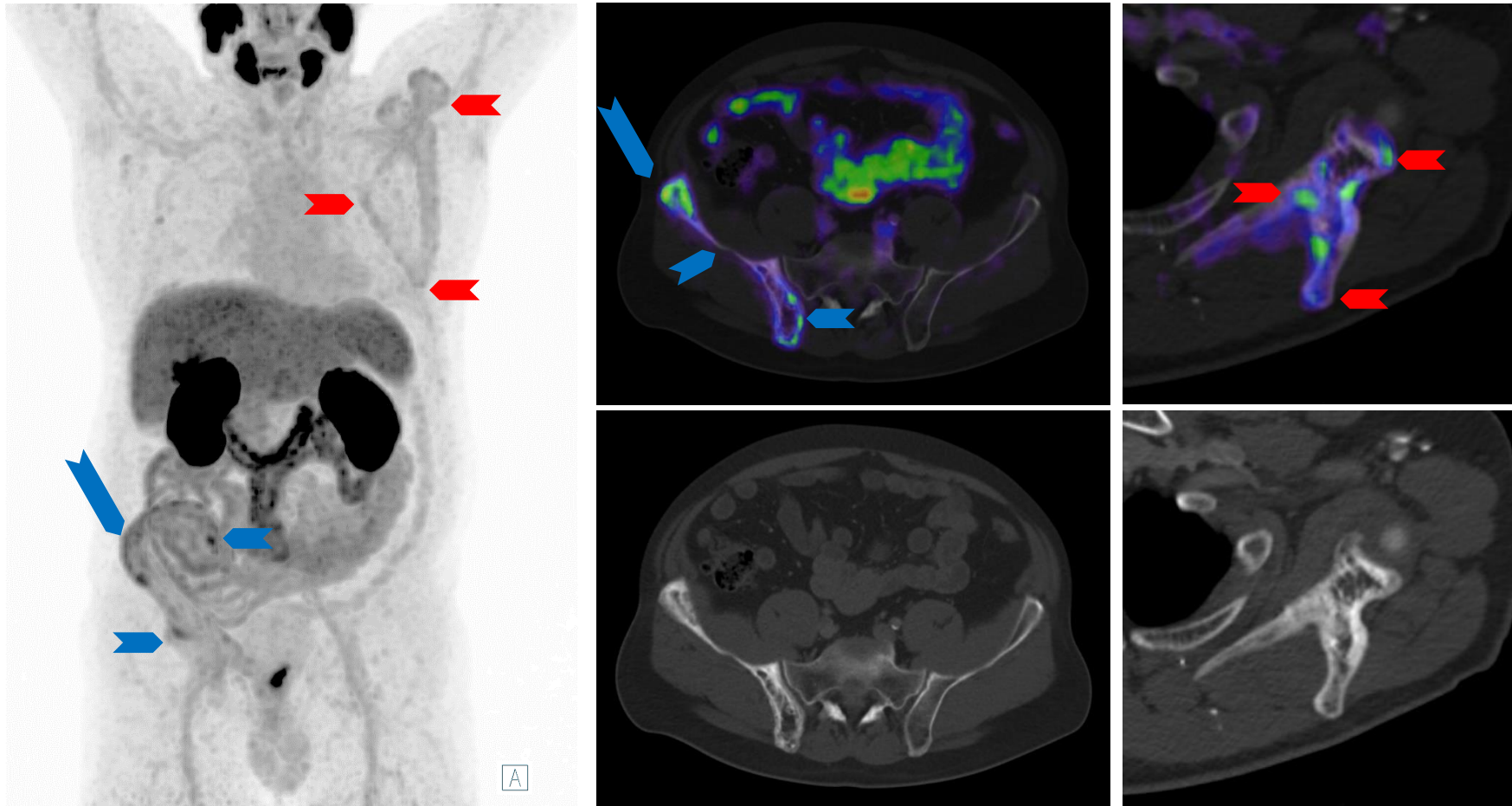
Specific Bone Uptake – Rib fracture



Rib fracture (blue arrow)

Images: University Hospital Essen, Department of nuclear medicine.

Specific Bone Uptake - Paget Disease



- Paget Disease of the right pelvis (blue arrows) and the left scapula (red arrows) with typical signs of cortical thickening and trabecular coarsening of the bone


- PSMA expression level may vary up to intense

Images: University Hospital Essen, Department of nuclear medicine.

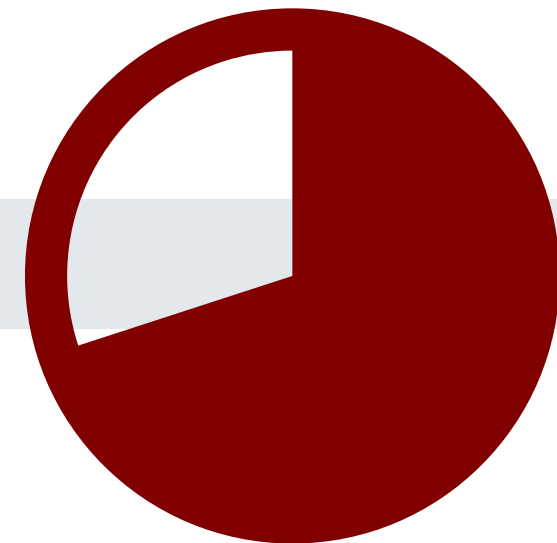
Specific Bone Uptake - Paget Disease



- Please click on the video icon on the right side to open the video or scan the QR code on the left side with your QR app on your smart phone!



Other Malignancies with PSMA Expression (examples)

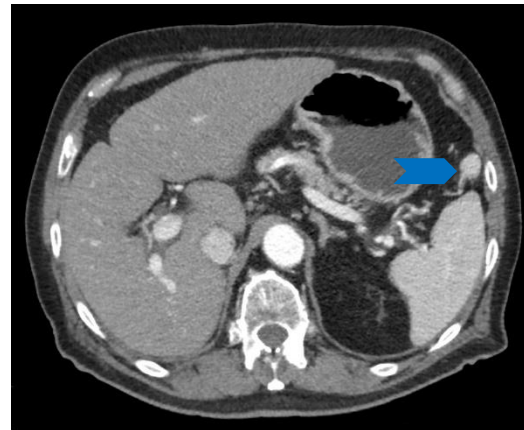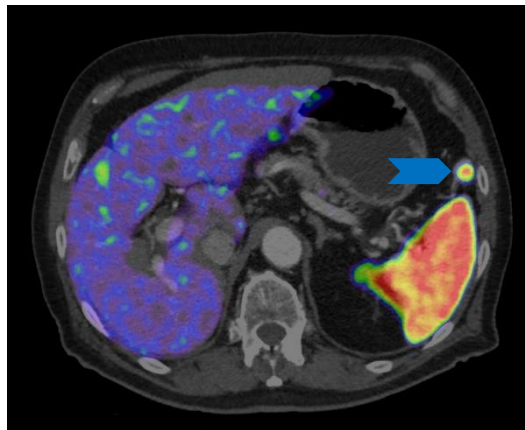
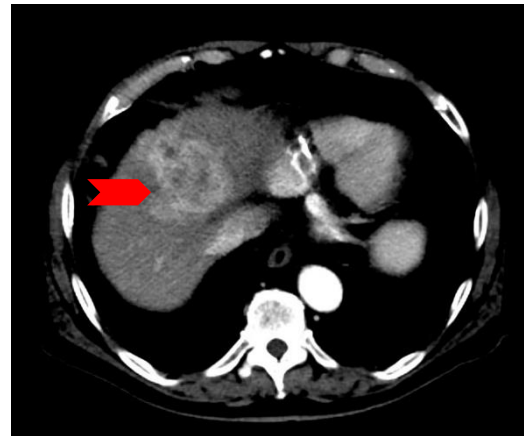
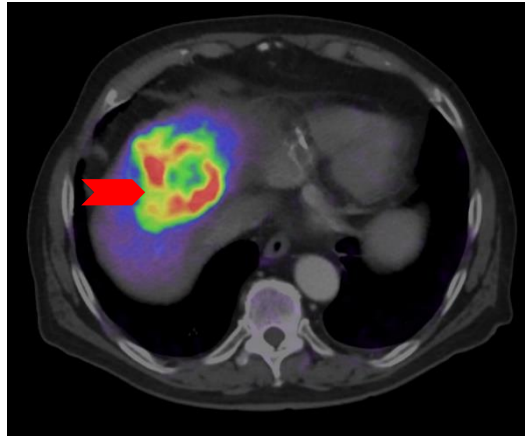
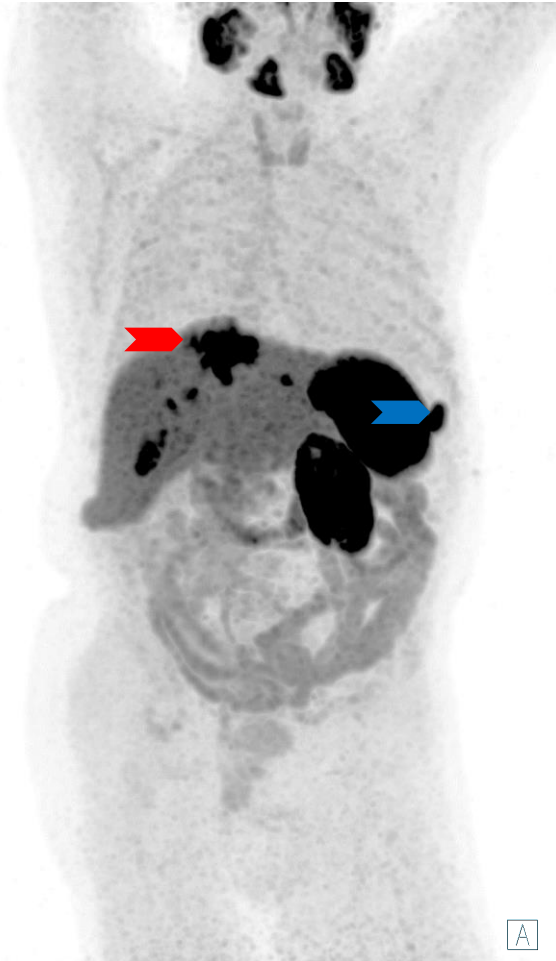


Other Malignancies with PSMA Uptake - Hepatocellular Carcinoma (HCC)

- As prostate cancer has a propensity to metastasize to the liver, it is crucial to conduct a comprehensive clinical evaluation and obtain an accurate medical history (including factors such as ISUP grade group, PSA levels, clinical history, and other potential organ metastases) to differentiate between primary liver lesions and metastatic prostate cancer.
 - The fact that liver metastases have a tendency to undergo de-differentiation further complicates the differentiation process based solely on PSMA uptake.
- Overall survival tended to be longer in patients without versus with PSMA expression (median overall survival: 4.2 vs. 1.9 years; $P = 0.273$).
- FGF14 (fibroblast growth factor 14) mRNA expression correlated positively ($\rho = 0.70$; $P = 1.70 \times 10^{-5}$) and MAD1L1 (Mitotic spindle assembly checkpoint protein MAD1) correlated negatively with PSMA expression ($\rho = -0.753$; $P = 1.58 \times 10^{-6}$).
- 31 patients with 39 HCC lesions completed PET; 64% ($n = 25$) lesions had a pronounced [^{68}Ga]PSMA-11 standardized uptake value: SUVmax (median [range] 9.2 [4.9-28.4]), SUVmean 4.7 (2.4-12.7)
- Ex vivo expression of PSMA in neovasculature of HCC translates to marked tumor avidity on [^{68}Ga]PSMA-11-PET, which suggests that PSMA has the potential as a theranostic target in patients with HCC.

*Thompson et al. Hepatol Commun. 2022 May;6(5):1172-1185.

Other Malignancies with PSMA Uptake - Hepatocellular Carcinoma (HCC)




- The majority of hepatocellular carcinomas (HCCs) exhibit elevated levels of PSMA expression, which can be identified through the utilization of PSMA PET/CT scans. Multiple HCC tumor lesions are present (exemplary red arrows). Accessory spleen (blue arrows)

Images: University Hospital Essen, Department of nuclear medicine.

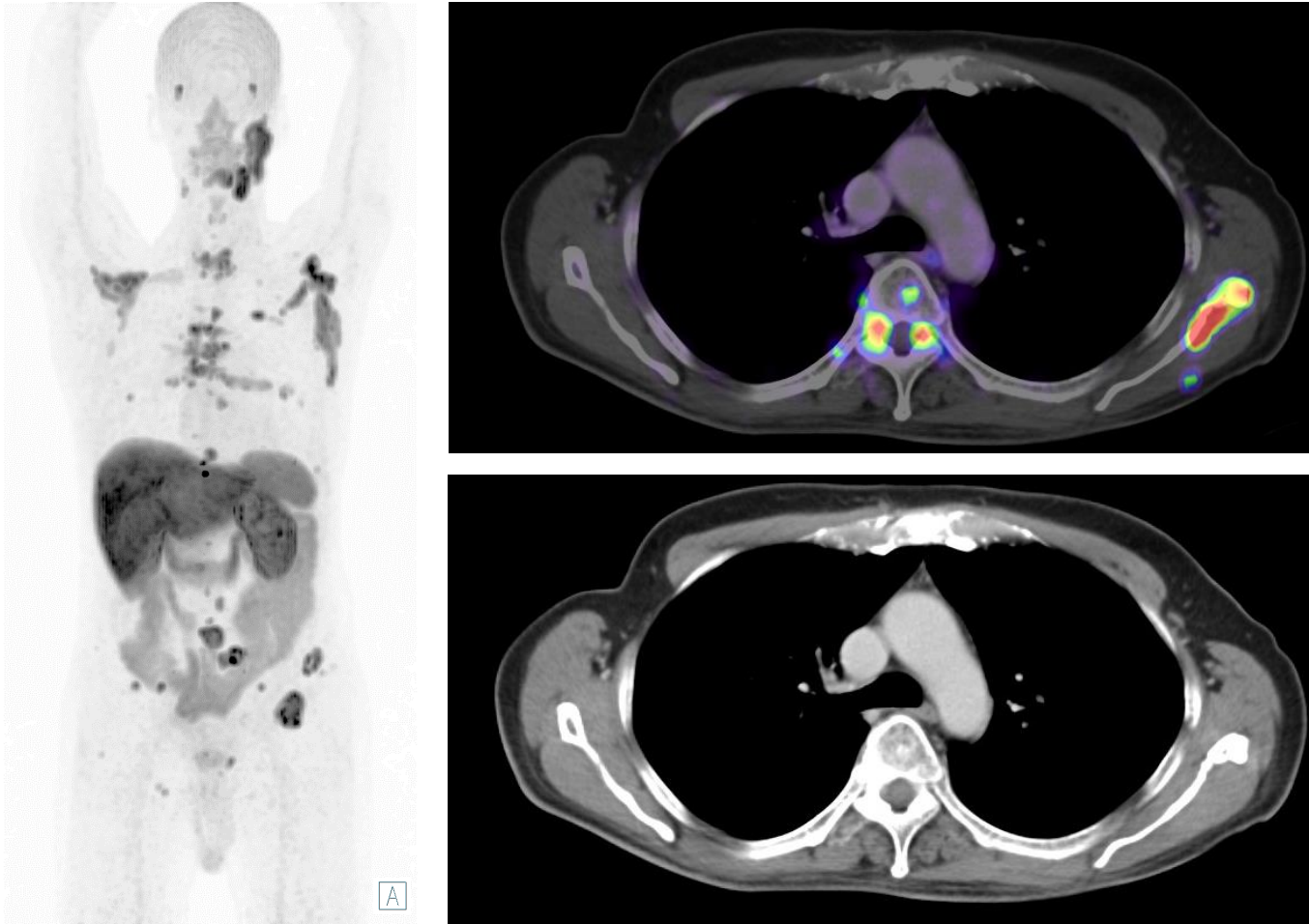
Other Malignancies with PSMA Uptake - Hepatocellular Carcinoma



- Please click on the video icon on the right side to open the video or scan the QR code on the left side with your QR app on your smart phone!



Other Malignancies with PSMA Uptake - Adenoid Cystic Carcinoma (ACC)



Images: University Hospital Essen, Department of nuclear medicine.


- Similar to the physiological expression of PSMA in the salivary glands, salivary gland carcinomas and their metastases may also exhibit heightened PSMA expression. Therefore, during every examination, it is imperative to perform individual windowing to differentiate between physiological uptake and potential pathological uptake in the salivary glands.
- The images show a patient with an ACC metastasized to bone. In the past, a resection of the right parotid gland or the primary tumor in the right parotid gland was performed.
- Despite the small number of studies and wide intra-patient and inter-tumor variation of PSMA uptake in ACC, PSMA PET has promising prospects as a diagnostic and radioligand therapeutic option [1]

[1] Tan BF et al. Cancers (Basel). 2022 Jul 22;14(15):3585


Other Malignancies with PSMA Uptake - Adenoid Cystic Carcinoma (ACC)



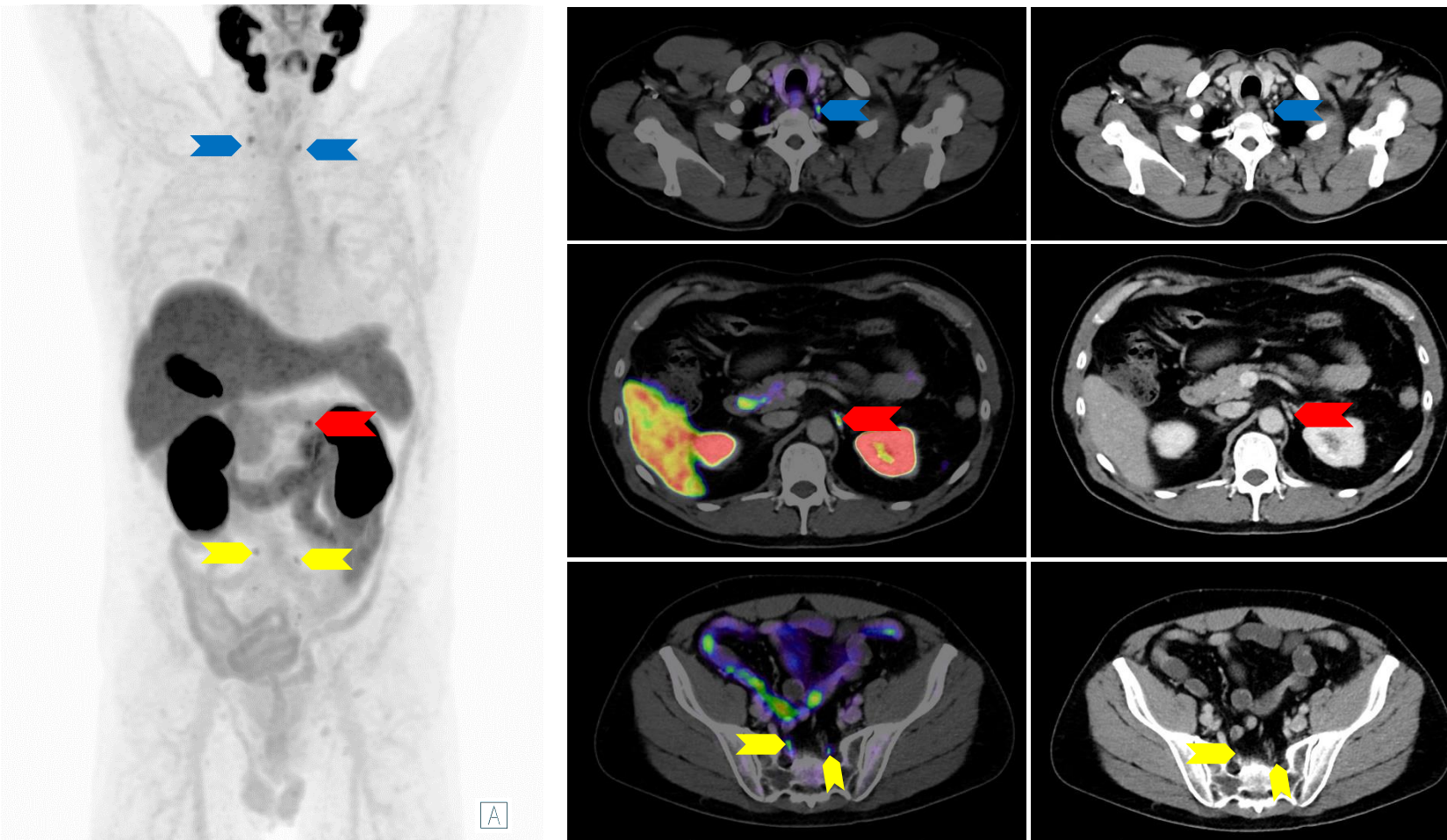
- Please click on the video icon on the right side to open the video or scan the QR code on the left side with your QR app on your smart phone!



Pitfalls



Pitfalls - Ganglia of the Sympathetic Trunk



- Physiological [^{18}F]PSMA-1007 uptake in Ganglia of the Sympathetic Trunk is very common
- In some cases it can be difficult to distinguish these from lymph node metastases. Useful criteria in the distinction of ganglia to lymph node metastases include:
 - Symmetrical occurrence
 - Specific anatomic landmarks (cervical (blue arrows), celiac, (red arrows), sacral (yellow arrows))
 - Band-shaped or teardrop configuration


Rischpler C, et al. J Nucl Med. 2018; 59(9):1406–1411.

Images: University Hospital Essen, Department of nuclear medicine.

Pitfalls - Ganglia of the Sympathetic Trunk



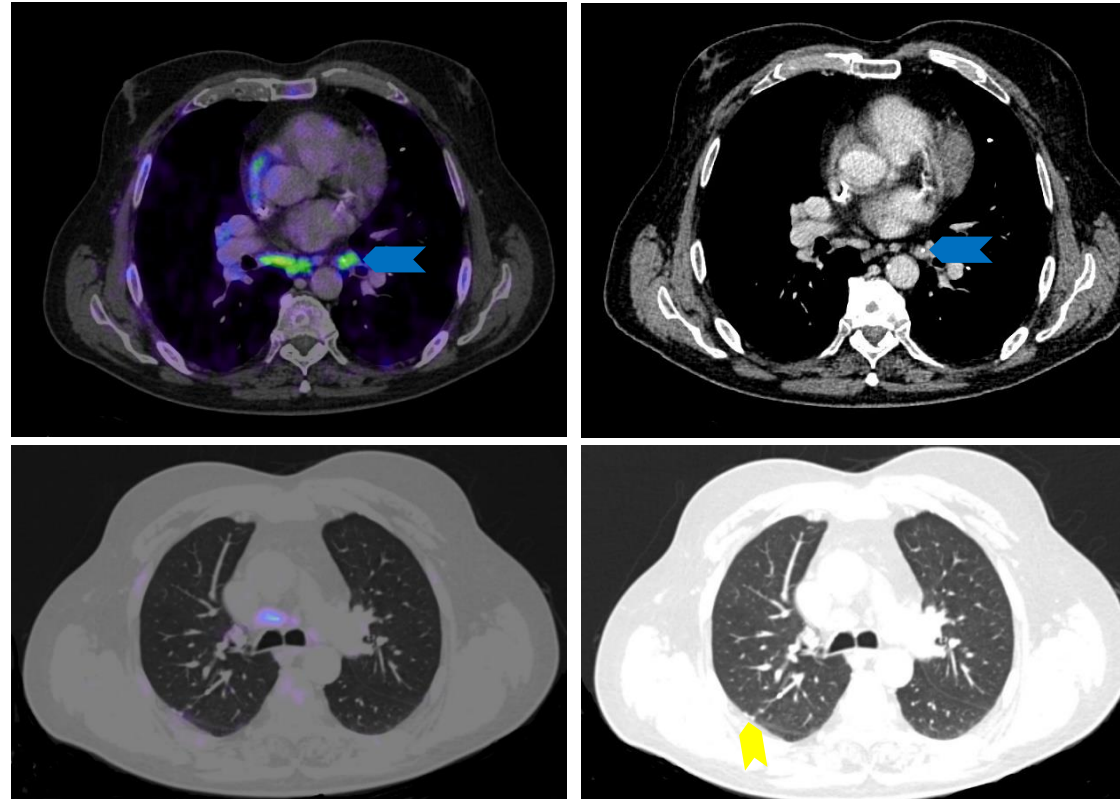
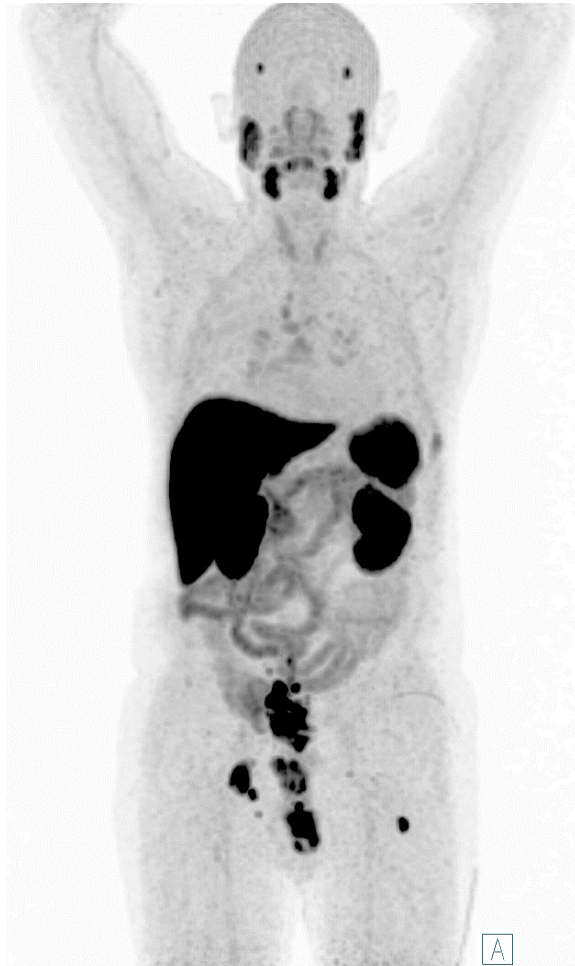
- Please click on the video icon on the right side to open the video or scan the QR code on the left side with your QR app on your smart phone!



Pitfalls - Sarcoidosis

- Similar to other cancer types and PET tracers, sarcoidosis can present a challenging differential diagnosis. The most frequent site of involvement in sarcoidosis is the biliary and mediastinal lymph nodes. Given that this is an infrequent site of metastasis in prostate cancer, typically occurring only in advanced stages, it is crucial to carefully examine the patient's medical history to determine the likelihood of such a metastatic pattern.

Pitfalls - Sarcoidosis



Dias AH, et al. Clin Nucl med. 2017; 42(3):e175-e176;
Ardies PJ, et al. Clin Nucl Med. 2017;42(4):303-305.


Images: University Hospital Essen, Department of nuclear medicine.

- Typical lung and mediastinal findings of sarcoidosis
 - Anterior mediastinum is spared
 - Hilar-Paratracheal lymph nodes - Symmetrical occurrence
 - 25-50% calcification+ (blue arrow)
 - <3 mm perilymphatic nodules
 - Bronchovascular, interlobular, subpleural nodules (yellow arrow)
 - Often upper lobes

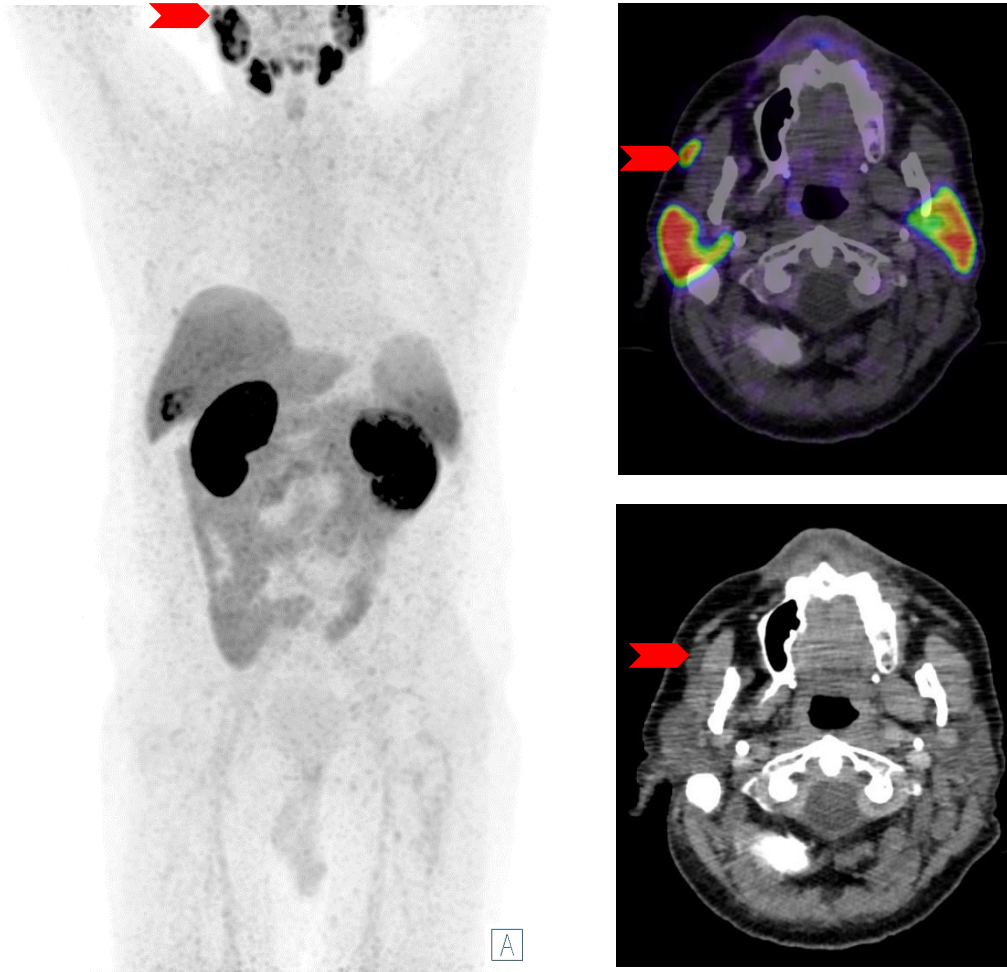
Pitfalls - Sarcoidosis



- Please click on the video icon on the right side to open the video or scan the QR code on the left side with your QR app on your smart phone!



Pitfalls - Accessory Salivary Glands




- Accessory salivary glands (red arrows), particularly those of the parotid gland, are a frequent anatomical variation and should not be mistaken for salivary gland malignancies or soft tissue metastases of prostate carcinoma.
- These are frequently found in the subcutaneous adipose tissue of the cheek or along the ducts of the salivary glands.

Images: University Hospital Essen, Department of nuclear medicine.

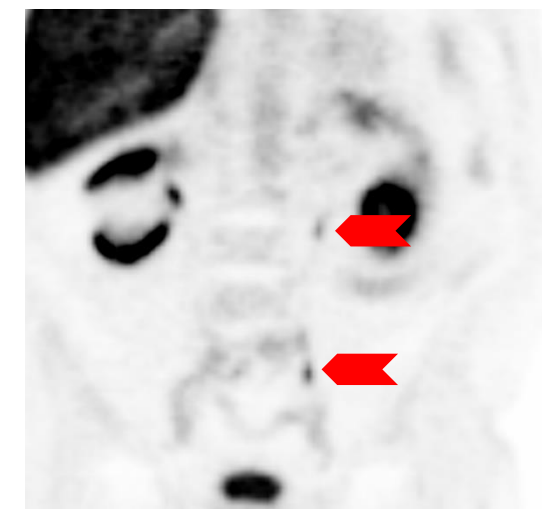
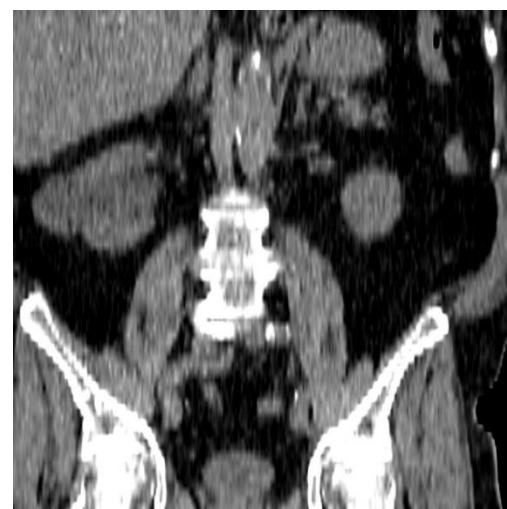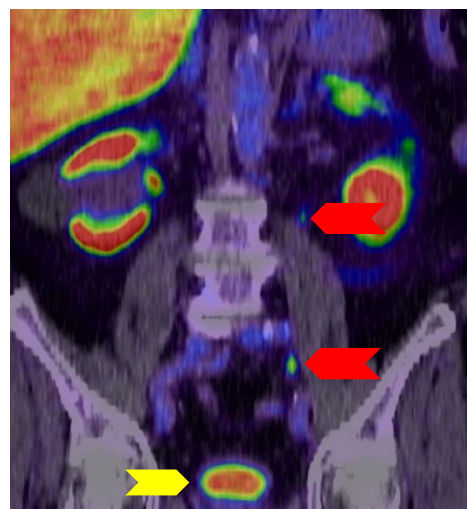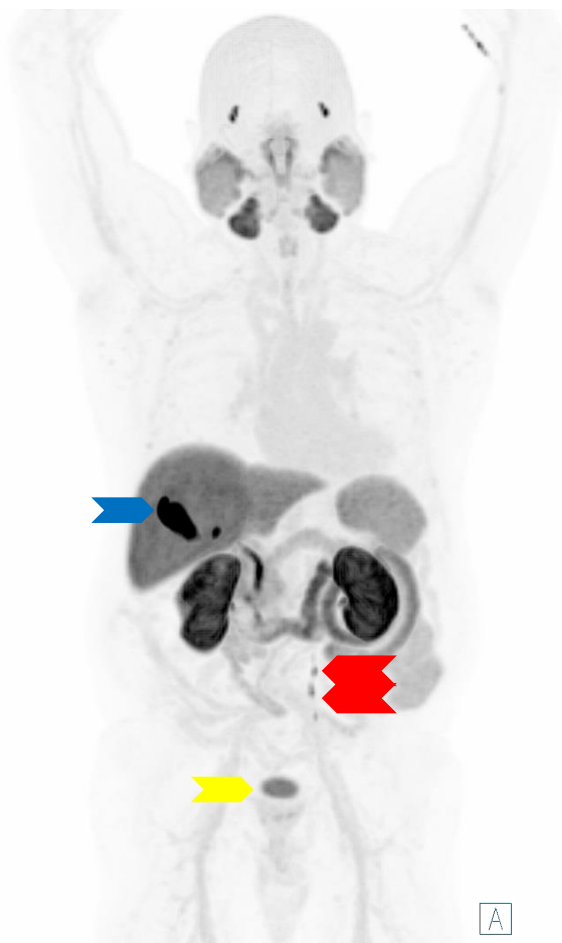
Pitfalls - Accessory Salivary Glands



- Please click on the video icon on the right side to open the video or scan the QR code on the left side with your QR app on your smart phone!



Pitfalls - Residual activity in the Bladder and Left Ureter




- $[^{18}\text{F}]$ PSMA-1007 is primarily excreted via the hepatobiliary system (blue arrow, gall bladder). The kidneys usually demonstrate intense PSMA expression, but only approximately 1% is excreted in the urine through the kidneys. Particularly in cases of prematurely acquired images and non-emptied bladder before image acquisition, there may be a faint urine activity (yellow arrows). [1]
 - This must not be mistaken for a local recurrence or an infiltrative tumor growing into the bladder.
- Furthermore, this activity can also be transiently observed in the ureters (red arrows). In such cases, distinguishing this activity from lymph node metastases can pose a challenge.

[1] Giesel FL, et al. Eur J Nucl Med Mol Imaging. 2017;44(4):678-688.
Images: University Hospital Essen, Department of nuclear medicine.

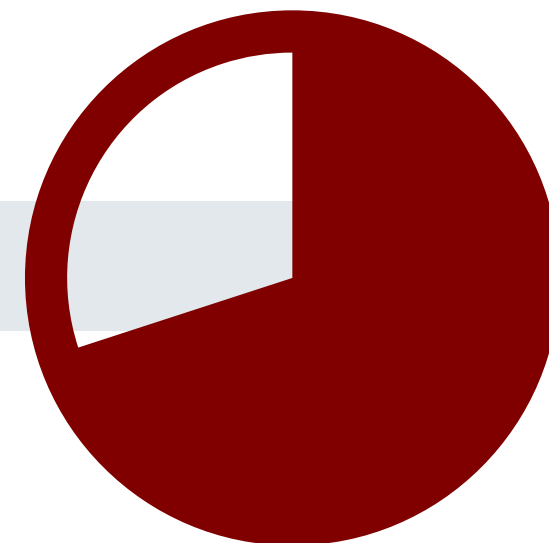
Pitfalls - Residual activity in the Bladder and Left Ureter



- Please click on the video icon on the right side to open the video or scan the QR code on the left side with your QR app on your smart phone!



Self-Evaluation Examination



Question 1

Which of the following organs does not show physiological [^{18}F]PSMA-1007 uptake?

- a) Parotid gland
- b) Spleen
- c) Liver
- d) Kidney
- e) Lungs

Question 1

Which of the following organs does not show physiological [^{18}F]PSMA-1007 uptake?

- a) Parotid gland
- b) Spleen
- c) Liver
- d) Kidney
- e) Lungs



Question 2

What is the target structure of [^{18}F]PSMA-1007?

- a) Prostate-specific membrane antigen (PSMA)
- b) Prostate-specific antigen (PSA)
- c) BRCA1/2
- d) Ki-67
- e) HER2

Question 2

What is the target structure of [^{18}F]PSMA-1007?

- a) Prostate-specific membrane antigen (PSMA)
- b) Prostate-specific antigen (PSA)
- c) BRCA1/2
- d) Ki-67
- e) HER2



Question 3

What is the suggested uptake time of [^{18}F]PSMA-1007?

- a) 15-30 minutes
- b) 30-60 minutes
- c) 60-90 minutes
- d) 90-120 minutes
- e) 120-150 minutes

Question 3

What is the suggested uptake time of [^{18}F]PSMA-1007?

- a) 15-30 minutes
- b) 30-60 minutes
- c) 60-90 minutes
- d) 90-120 minutes
- e) 120-150 minutes



Question 4

What are typical side-effects of the application of [^{18}F]PSMA-1007?

- a) Nausea
- b) Diarrhea
- c) Urinary tract infection
- d) Xerostomia / Dry mouth
- e) None of the above

Question 4

What are typical side-effects of the application of [^{18}F]PSMA-1007?

- a) Nausea
- b) Diarrhea
- c) Urinary tract infection
- d) Xerostomia / Dry mouth
- e) None of the above



Question 5

Which of the following poses an on-label indication for the use of [^{18}F]PSMA-1007?

- a) Primary Staging of Patients with High-Risk Prostate Cancer
- b) Primary Staging of Patients with low- to mid-Risk Prostate Cancer
- c) Screening for Prostate Cancer in male Patients over 35
- d) Primary Staging of Patients with a suspicion of Prostate Cancer to avoid biopsy
- e) Restaging of Patients with HCC after local ablation

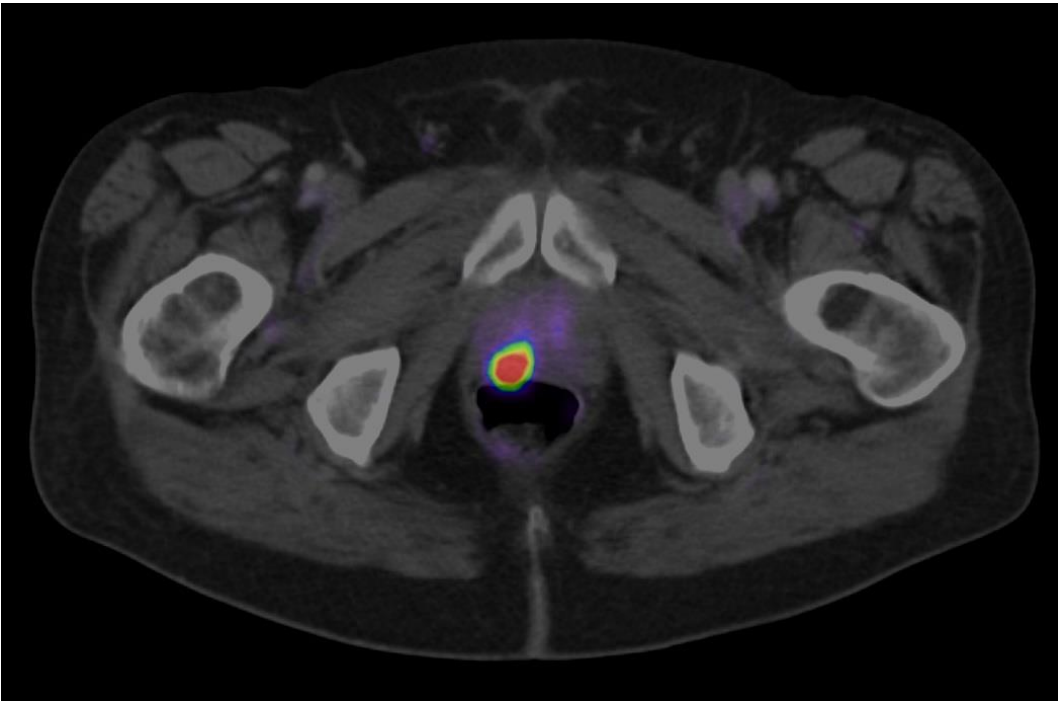
Question 5

Which of the following poses an on-label indication for the use of [^{18}F]PSMA-1007?

- a) Primary Staging of Patients with High-Risk Prostate Cancer
- b) Primary Staging of Patients with low- to mid-Risk Prostate Cancer
- c) Screening for Prostate Cancer in male Patients over 35
- d) Primary Staging of Patients with a suspicion of Prostate Cancer to avoid biopsy
- e) Restaging of Patients with HCC after local ablation



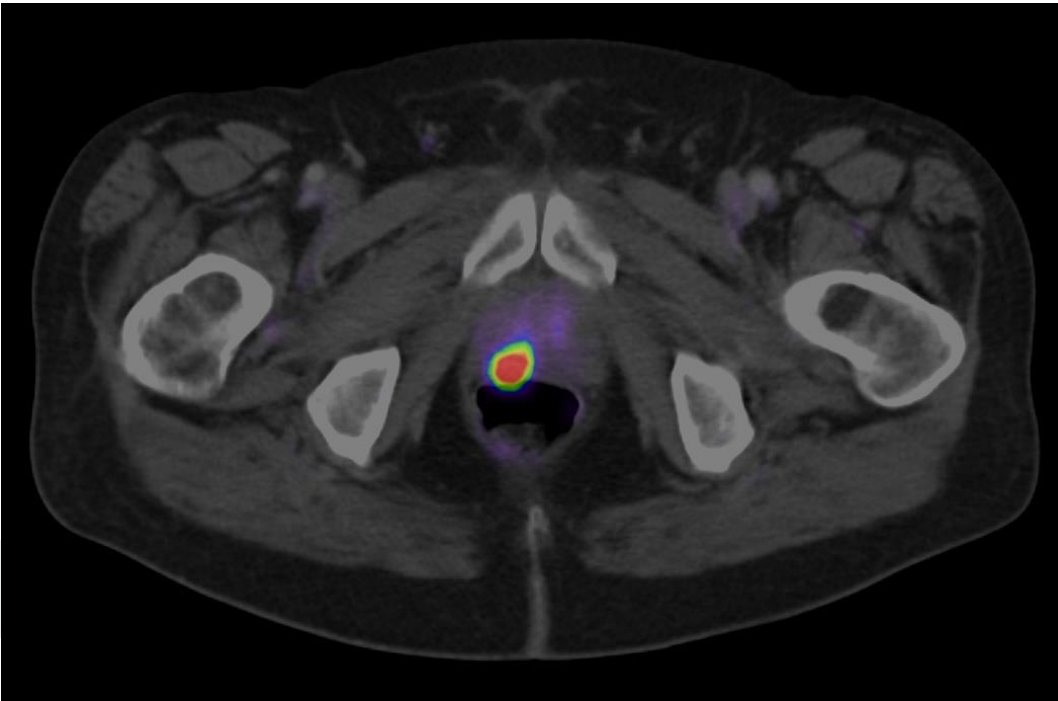
Question 6



What is the most-probable reason for the high Tracer Uptake in the right lobe of the prostate in the image?

- a) Urine contamination
- b) (Residual) Urine activity in the urethra
- c) Unspecific bone uptake
- d) Diverticulitis of the colon
- e) Unifocal prostate cancer

Question 6

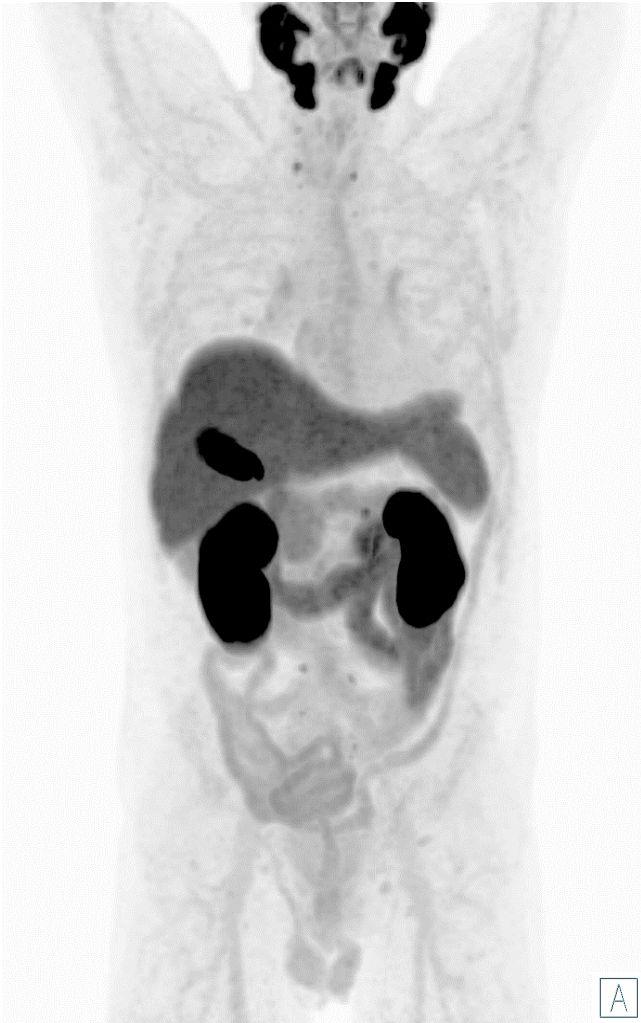

What is the most-probable reason for the high Tracer Uptake in the right lobe of the prostate in the image?

- a) Urine contamination
- b) (Residual) Urine activity in the urethra
- c) Unspecific bone uptake
- d) Diverticulitis of the colon
- e) Unifocal prostate cancer



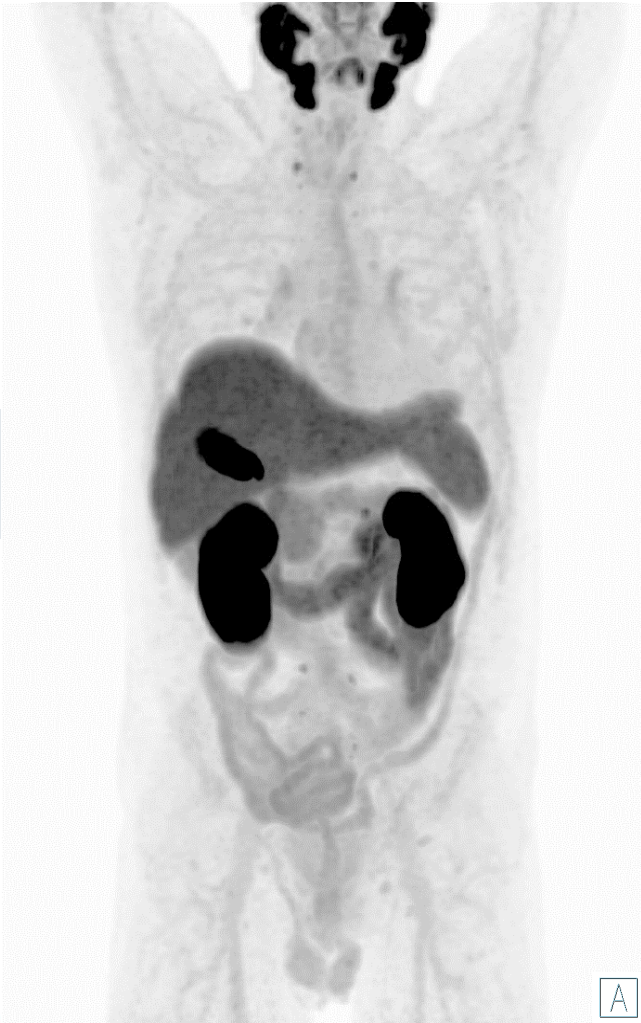Question 7



What is the most-probable diagnosis?

- a) Single liver metastasis
- b) Cervical lymph node metastases
- c) No tumor with elevated PSMA expression, physiological distribution
- d) Bilateral Adenoid Cystic Carcinoma (ACC)
- e) Unifocal prostate cancer

Question 7

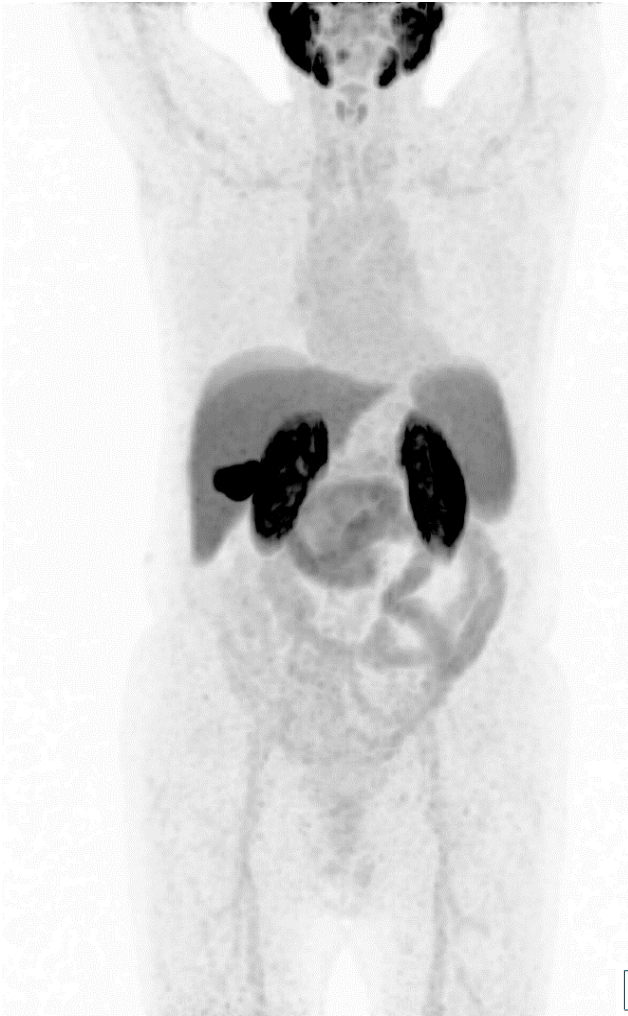

What is the most-probable diagnosis?

- a) Single liver metastasis
- b) Cervical lymph node metastases
- c) No tumor with elevated PSMA expression, physiological distribution
- d) Bilateral Adenoid Cystic Carcinoma (ACC)
- e) Unifocal prostate cancer



Question 8

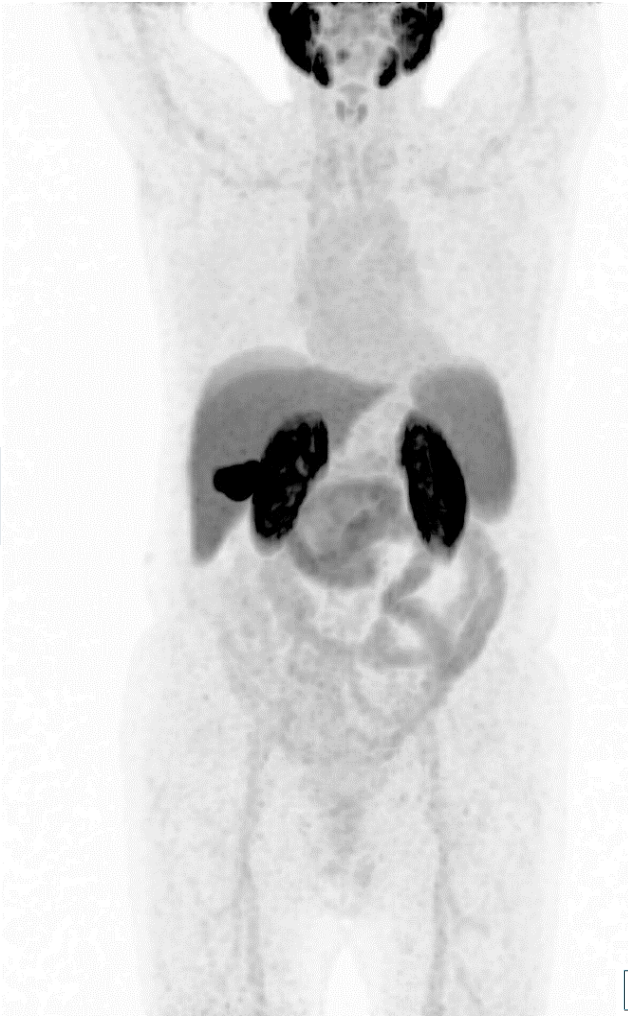

Which PSMA tracer was used?

- a) [^{68}Ga]Ga-PSMA-11
- b) [^{68}Ga]Ga-PSMA-I&T
- c) [^{18}F]DCFPyL
- d) [^{18}F]PSMA-1007
- e) [$^{99\text{m}}\text{Tc}$]Tc-MIP1404

A

Question 8

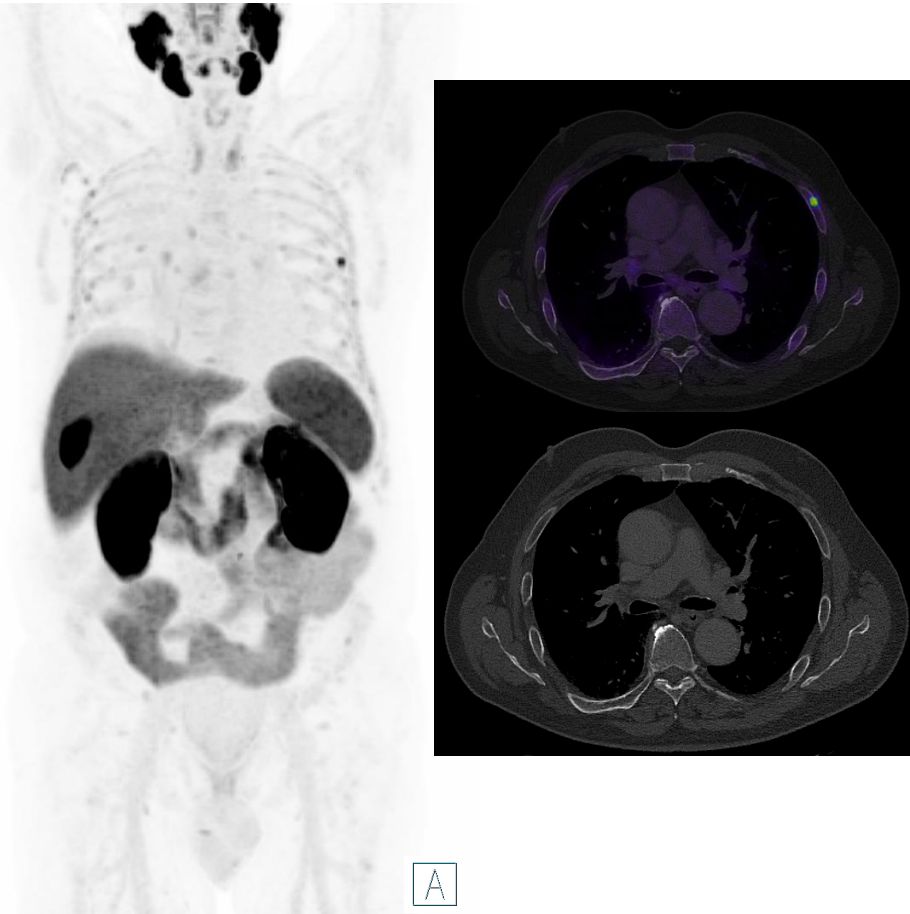


Which PSMA tracer was used?

- a) [^{68}Ga]Ga-PSMA-11
- b) [^{68}Ga]Ga-PSMA-I&T
- c) [^{18}F]DCFPyL
- d) [^{18}F]PSMA-1007
- e) [$^{99\text{m}}\text{Tc}$]Tc-MIP1404



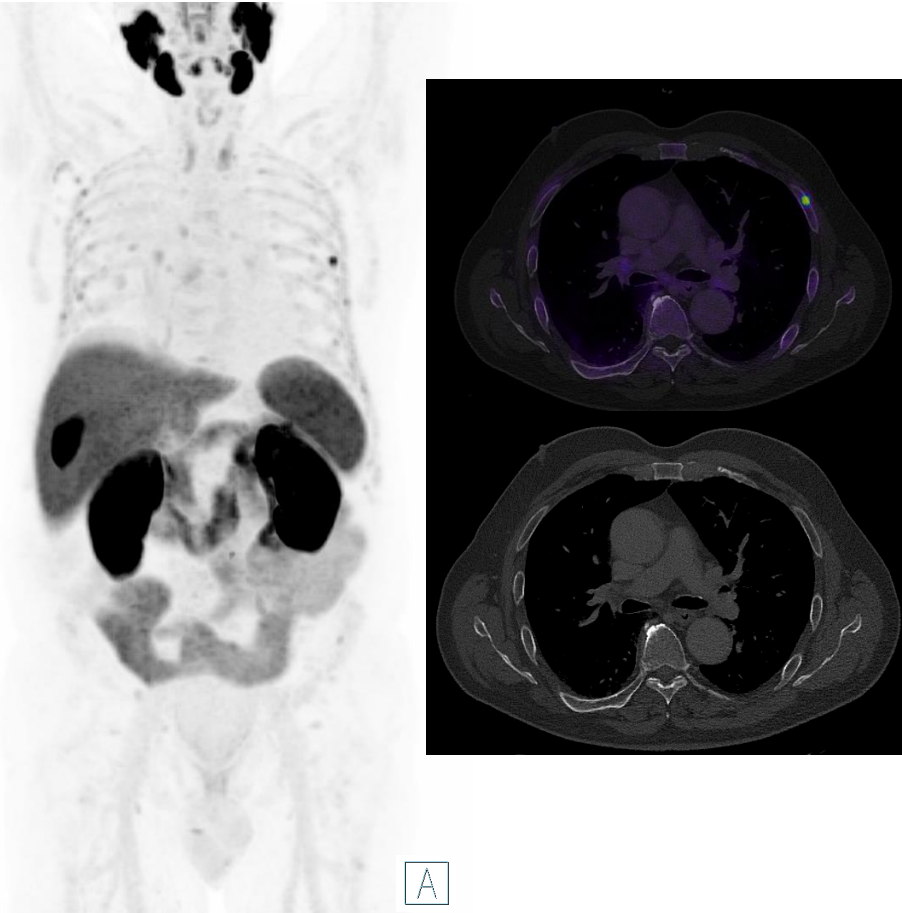
Question 9



High risk patient with BCR (PSA: 0.45 ng/ml). What is the most-probable diagnosis and the most appropriate suggestion?

- a) Unspecific uptake in the rib; possibly benign - MRI is recommended
- b) Unspecific uptake in the rib, possibly benign - Bone scan is recommended
- c) Bone marrow infiltration - MRI is recommended
- d) Single bone metastasis - MRI is recommended
- e) Bone fracture, possibly benign - follow-up is recommended

Question 9

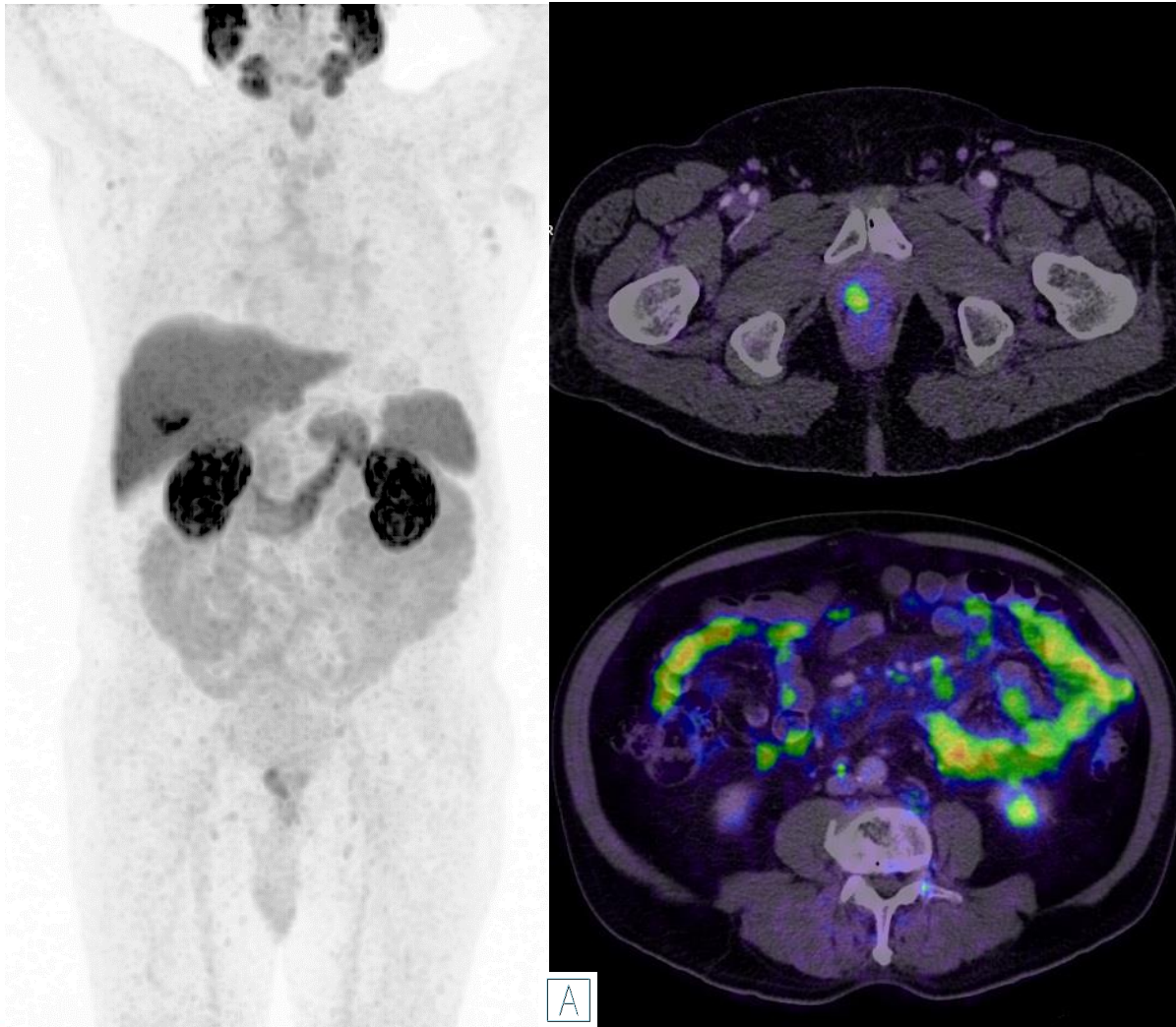


High risk patient with BCR (PSA: 0.45 ng/ml). What is the most-probable diagnosis and the most appropriate suggestion?

- a) Unspecific uptake in the rib; possibly benign - MRI is recommended
- b) Unspecific uptake in the rib, possibly benign - Bone scan is recommended
- c) Bone marrow infiltration - MRI is recommended
- d) Single bone metastasis - MRI is recommended
- e) Bone fracture, possibly benign - follow-up is recommended



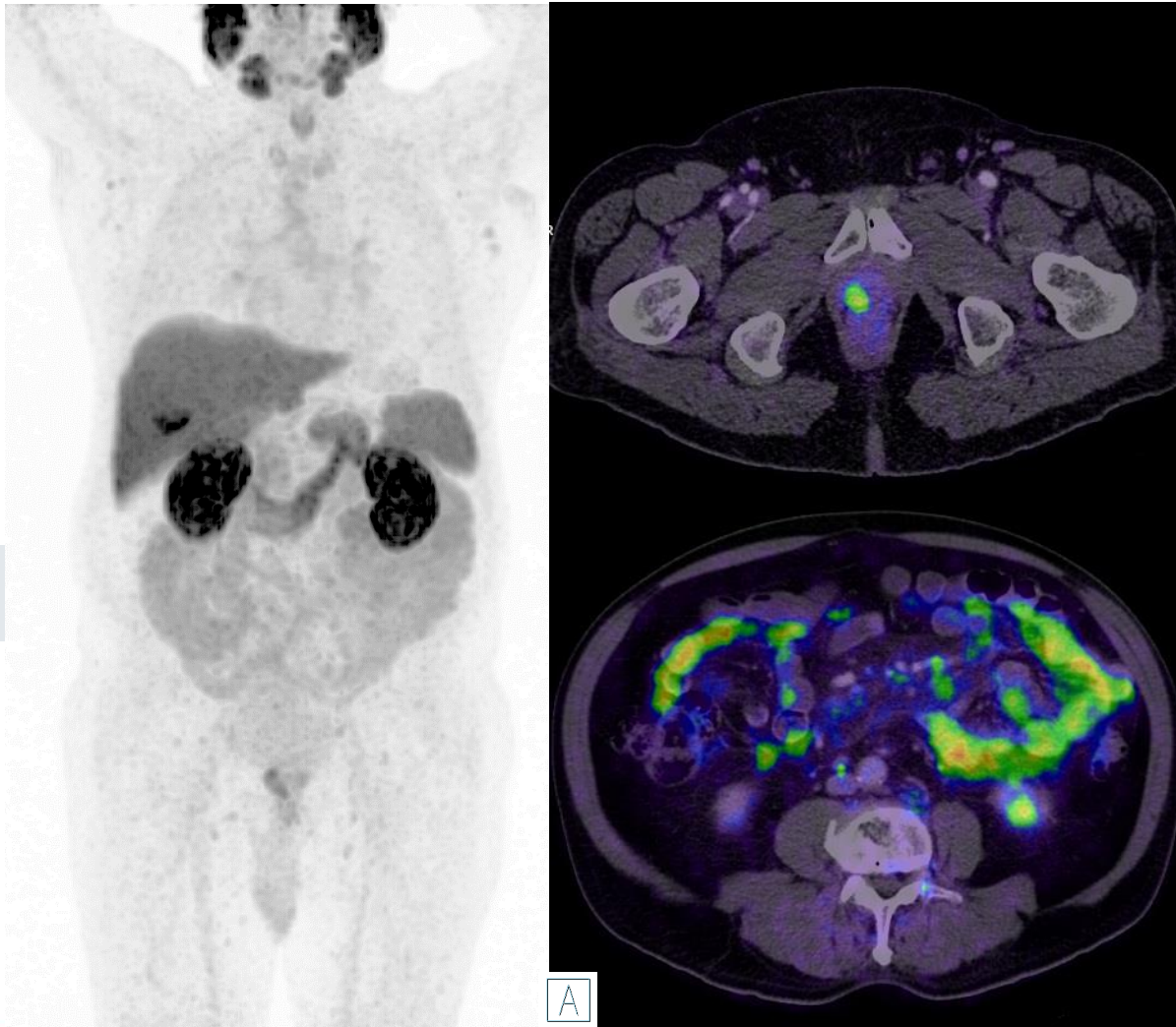
Question 10



High risk patient initial staging. What is the most-probable diagnosis?

- a) T2u N0 M0
- b) T2u N0 M1a
- c) T2u N0 M1c
- d) T2u N0 M0 + Panniculitis
- e) T2u N1 M1a M1c

Question 10



High risk patient initial staging. What is the most-probable diagnosis?

- a) T2u N0 M0
- b) T2u N0 M1a
- c) T2u N0 M1c
- d) T2u N0 M0 + Panniculitis
- e) T2u N1 M1a M1c



List of Supplementary Videos

Page number	Case video	Link directly to the video
30	Introduction to Image Reading and Physiological Distribution of [¹⁸F]PSMA-1007	https://youtu.be/aqr5bGQTJmI
34	Primary Staging - Unifocal Tumor	https://youtu.be/MDFH3A-4kvA
36	Primary Staging - Multifocal Tumor	https://youtu.be/CEYXj1unqRE
38	Primary Staging - Multifocal Tumor with Pelvic Lymph Node Metastases	https://youtu.be/H2FR72wtAyQ
40	Primary Staging - Multifocal Tumor with Distant Metastases	https://youtu.be/sKGSJRgFORl
43	Restaging - Local Recurrence (Case 1)	https://youtu.be/Lj-aSim5_Tc
46	Restaging - Local Lymph Node Metastasis (Iliac)	https://youtu.be/uf-ULs-mezc
50	Restaging - Distant Lymph Node Metastases (Supraclavicular-Virchow`s Lymph Node)	https://youtu.be/0GmAzPs7doo
52	Restaging - Lung Metastases (Case 1)	https://youtu.be/utWz8ABkp5s
55	Restaging - Single Bone Metastasis	https://youtu.be/C--zYWIIIXV4
66	Unspecific Bone Uptake	https://youtu.be/rsvC9uQNi7A
72	Specific Bone Uptake - Paget Disease	https://youtu.be/UnRbzLoV7f0
76	Other Malignancies with PSMA Uptake - Hepatocellular Carcinoma	https://youtu.be/Nadt5l1q3Go
78	Other Malignancies with PSMA Uptake - Adenoid Cystic Carcinoma (ACC)	https://youtu.be/OMTKc7x1PWs
81	Pitfalls - Ganglia of the Sympathetic Trunk	https://youtu.be/D2FJEaylfrI
84	Pitfalls – Sarcoidosis	https://youtu.be/-hQCfA-vQcU
86	Pitfalls - Accessory Salivary Gland	https://youtu.be/MJc9uzioCuk
88	Pitfalls - Residual activity in the Bladder and Left Ureter	https://youtu.be/4x6Vjlll2o

Abbreviation List

ACC	Adenoid Cystic Carcinoma	MRI	Magnetic resonance imaging
BCR	Biochemical Recurrence	NAAG	N-acetylaspartylglutamate
CT	Computed tomography	NAA	N-acetylaspartate
DMI	Diffuse bone-marrow infiltration	PET	positron emission tomography
EANM	European Association of Nuclear Medicine	PSA	prostate-specific antigen
ESUR	EAU Section of Urological Research	PSMA	prostate-specific membrane antigen
GCPII	glutamate carboxypeptidase II	SNMMI	Society of Nuclear Medicine and Molecular Imaging
HCC	hepatocellular carcinoma	SUV	Standardized Uptake Value
ISUP	International Society of Urological Pathology	UBU	Unspecific bone uptake
MIP	Maximum intensity projection		

Bibliography

- Demirci, E., et al. (2016). "Normal distribution pattern and physiological variants of 68Ga-PSMA-11 PET/CT imaging." Nucl Med Commun **37**(11): 1169-1179.
- Ristau, B. T., et al. (2014). The prostate-specific membrane antigen: lessons and current clinical implications from 20 years of research. Urologic Oncology: Seminars and Original Investigations, Elsevier.
- Fendler, W. P., et al. (2017). "(68)Ga-PSMA PET/CT: Joint EANM and SNMMI procedure guideline for prostate cancer imaging: version 1.0." Eur J Nucl Med Mol Imaging **44**(6): 1014-1024.
- Eiber, M., et al. (2018). "Prostate cancer molecular imaging standardized evaluation (PROMISE): proposed miTNM classification for the interpretation of PSMA-ligand PET/CT." Journal of Nuclear Medicine **59**(3): 469-478.
- Anttinen, M., et al. (2021). "A Prospective Comparison of (18)F-prostate-specific Membrane Antigen-1007 Positron Emission Tomography Computed Tomography, Whole-body 1.5 T Magnetic Resonance Imaging with Diffusion-weighted Imaging, and Single-photon Emission Computed Tomography/Computed Tomography with Traditional Imaging in Primary Distant Metastasis Staging of Prostate Cancer (PROSTAGE)." Eur Urol Oncol **4**(4): 635-644.
- Sprute, K., et al. (2021). "Diagnostic Accuracy of (18)F-PSMA-1007 PET/CT Imaging for Lymph Node Staging of Prostate Carcinoma in Primary and Biochemical Recurrence." J Nucl Med **62**(2): 208-213.
- Hermesen, R., et al. (2022). "Lymph node staging with fluorine-18 prostate specific membrane antigen 1007-positron emission tomography/computed tomography in newly diagnosed intermediate- to high-risk prostate cancer using histopathological evaluation of extended pelvic node dissection as reference." Eur J Nucl Med Mol Imaging **49**(11): 3929-3937.
- Ingvar, J., et al. (2022). "Assessing the accuracy of [(18)F]PSMA-1007 PET/CT for primary staging of lymph node metastases in intermediate- and high-risk prostate cancer patients." EJNMMI Res **12**(1): 48.

Bibliography

- Giesel, F. L., et al. (2017). "F-18 labelled PSMA-1007: biodistribution, radiation dosimetry and histopathological validation of tumor lesions in prostate cancer patients." Eur J Nucl Med Mol Imaging **44**(4): 678-688.
- Privé, B. M., et al. (2021). "Evaluating F-18-PSMA-1007-PET in primary prostate cancer and comparing it to multi-parametric MRI and histopathology." Prostate Cancer Prostatic Dis **24**(2): 423-430.
- Giesel, F. L., et al. (2019). "Detection Efficacy of (18)F-PSMA-1007 PET/CT in 251 Patients with Biochemical Recurrence of Prostate Cancer After Radical Prostatectomy." J Nucl Med **60**(3): 362-368.
- Ulano, A., et al. (2016). "Distinguishing Untreated Osteoblastic Metastases From Enostoses Using CT Attenuation Measurements." AJR Am J Roentgenol **207**(2): 362-368.
- Ma, B., et al. (2021). "Prostate cancer liver metastasis: Dormancy and resistance to therapy." Semin Cancer Biol **71**: 2-9.
- Arnfield, E. G., et al. (2021). "Clinical insignificance of [(18)F]PSMA-1007 avid non-specific bone lesions: a retrospective evaluation." Eur J Nucl Med Mol Imaging **48**(13): 4495-4507.
- Seifert, R., et al. (2023). "Unspecific (18)F-PSMA-1007 Bone Uptake Evaluated Through PSMA-11 PET, Bone Scanning, and MRI Triple Validation in Patients with Biochemical Recurrence of Prostate Cancer." J Nucl Med **64**(5): 738-743.
- Thompson, S. M., et al. (2022). "PSMA as a Theranostic Target in Hepatocellular Carcinoma: Immunohistochemistry and (68) Ga-PSMA-11 PET Using Cyclotron-Produced (68) Ga." Hepatol Commun **6**(5): 1172-1185.
- Tan, B. F., et al. (2022). "PSMA PET Imaging and Therapy in Adenoid Cystic Carcinoma and Other Salivary Gland Cancers: A Systematic Review." Cancers (Basel) **14**(15).

Bibliography

- Rischpler, C., et al. (2018). "68Ga-PSMA-HBED-CC uptake in cervical, celiac, and sacral ganglia as an important pitfall in prostate cancer PET imaging." Journal of Nuclear Medicine **59**(9): 1406-1411.
- Dias, A. H., et al. (2017). "Prostate-Specific Membrane Antigen PET/CT: Uptake in Lymph Nodes With Active Sarcoidosis." Clin Nucl Med **42**(3): e175-e176.
- Ardies, P. J., et al. (2017). "PSMA Uptake in Mediastinal Sarcoidosis." Clin Nucl Med **42**(4): 303-305.c

Adverse Event Reporting

Melden van bijwerkingen

De gezondheidszorgbeoefenaars worden verzocht de bijwerkingen en ook mogelijke medicatie- fouten, geassocieerd met het gebruik van Radelumin® te melden aan de afdeling Vigilantie van het FAGG. Het melden kan bij voorkeur online gebeuren via www.eenbijwerkingmelden.be of anders via de “papieren meldingsfiche” die op verzoek verkrijgbaar is bij het FAGG of die kan worden afgedrukt op de website van het FAGG, www.fagg.be. De ingevulde papieren meldingsfiche kan per post verzonden worden naar het adres FAGG – afdeling Vigilantie – Galileelaan 5/03– 1210 Brussel, per fax op het nummer 02/528.40.01, of per mail naar: adr@fagg.be.

Notification des effets indésirables

Belgique

Les professionnels de la santé sont invités à notifier les effets indésirables ainsi que les éventuelles erreurs médicamenteuses liés à l'utilisation de Radelumin® à la division Vigilance de l'AFMPS. La notification peut se faire de préférence en ligne via www.notifieruneffetindesirable.be, sinon à l'aide de la « fiche de notification en version papier » disponible sur demande à l'AFMPS ou imprimable à partir du site internet de l'AFMPS www.afmps.be. La « fiche de notification en version papier » remplie peut être envoyée par la poste à l'adresse AFMPS – Division Vigilance – Avenue Galilée 5/03 – 1210 Bruxelles, par fax au numéro 02/528.40.01, ou encore par email à : adr@afmps.be.

Grand-Duché du Luxembourg :

Les effets indésirables sont à notifier à Centre Régional de Pharmacovigilance de Nancy ou Division de la pharmacie et des médicaments de la Direction de la santé

Site internet : www.guichet.lu/pharmacovigilance



Thank you

Educational Material for HCPs
[¹⁸F]PSMA-1007 image interpretation training